



PATIENT

Gordie Armstrong

PRESENTING CLINICAL SIGNS

coughing daily, congested, mouth breathing
Abnormal PE/Chem/CBC/UA Results: QAR

SPECIES

Feline

RADIOGRAPHIC STUDY OF THE THORAX

Right/left lateral and ventrodorsal views totaling 4 images available for review.

BREED

Domestic Shorthair

RADIOGRAPHIC FINDINGS

The lungs are moderately inflated. A moderate generalized bronchial lung pattern with caudodorsal accentuation and peribronchial cuffing is noted. Occasional pleural plaques/pulmonary osteomas are seen.

SEX

Neutered Male

There is moderate esophageal and gastric aerophagia.

The radiographic presentation of the cardiac silhouette and pulmonary vasculature is within normal limits.

AGE

8 Years

Course and width of the trachea are considered within normal limits.

There is no evidence of mediastinal widening.

INTERPRETED BY

Nele Eley, DVM
Dr. med. Vet. DipECVDI

RADIOGRAPHIC DIAGNOSIS

- Moderate bronchial lung pattern.

HOSPITAL NAME

Truscott Animal
Hospital

INTERPRETATION OF THE FINDINGS & FURTHER RECOMMENDATIONS

The radiographic findings are compatible with lower airway disease. Allergic lower airway syndrome is a primary differential diagnosis as well as infectious bronchitis such as viral, bacterial, parasitic, or protozoal. Consider a clinical trial of treatment for feline asthma if not performed already. If this has proven unsuccessful, further definition by means of airway sampling could be considered. Proactive deworming may be performed.

REFERRING VET

Dr. Medhat Meawad

INVOICE

54470

DATE

10-5-22



PATIENT

Gordie Armstrong

SPECIES

Feline

BREED

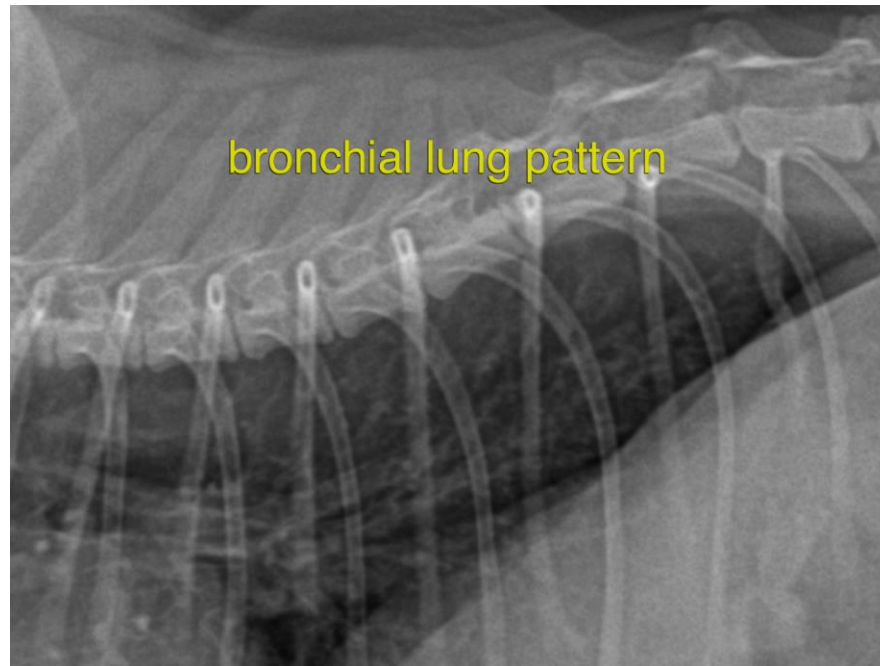
Domestic Shorthair

SEX

Neutered Male

AGE

8 Years



INTERPRETED BY

Nele Eley, DVM
Dr. med. Vet. DipECVDI

The information and recommendations provided are based on the images presented by the referring veterinarian/sonographer. No evaluation can be communicated regarding pathology that was not visible in the image/video clips provided.

Thank you for this referral. If the clinical or image interpretation does not parallel your findings or if I can be of any further assistance please contact me.

HOSPITAL NAME

Truscott Animal
Hospital

Nele Eley, DVM, Dr. med. vet., DipECVDI
European Specialist in Veterinary Diagnostic Imaging, Cert. Radiology,
Senior lecturer University of Giessen, Germany, Veterinary Faculty, Department of Radiology
Nele.Eley@sonopath.com

REFERRING VET

Dr. Medhat Meawad

INVOICE

54470

DATE

10-5-22