

**PATIENT**

Theo Bartosic

PRESENTING CLINICAL SIGNS

Theo is a seven year old, MN, DSH cat who lives indoors. Last evening, Theo's owner came home to find him in his bed where he had apparently been all day. He had urinated in his bed. When she got Theo out of the bed, he was non-weight bearing on his left hindlimb. On exam, Theo is very painful on left hip palpation and is non-weight bearing on that leg.

SPECIES

Feline

RADIOGRAPHIC STUDY OF THE PELVIS

Lateral and ventrodorsal views of the pelvis totaling 4 images available for review.

BREED

DSH

RADIOGRAPHIC FINDINGS

The left femoral head is luxated dorsally and cranially. There is subchondral bone sclerosis of the acetabulum and left femoral head. No evidence of fracture of the acetabulum or left femur is seen.

SEX

MN

The conformation of the acetabular is shallow on both sides. A mild amount of periarticular osteophytes are seen in the acetabulum in the left and right coxofemoral joint.

AGE

7 Years

The right coxofemoral joint is in situ; however, the femoral head coverage is reduced to approximately 30% of the femoral head diameter.

Moderate lumbosacral stenosis and vertebral end plate sclerosis is seen.

INTERPRETED BY

Nele Eley, DVM
Dr. med. Vet. DipECVDI

RADIOGRAPHIC DIAGNOSIS

- Craniodorsal luxation of the left femoral head.
- Bilateral feline hip dysplasia with mild secondary osteoarthritic changes.
- Mild to moderate degenerative lumbosacral stenosis.

HOSPITAL NAME

Lambs Gap Animal
Hospital

INTERPRETATION OF THE FINDINGS & FURTHER RECOMMENDATIONS

Spontaneous cranial and dorsal luxation of the left femoral head secondary to increased coxofemoral joint laxity is likely. There is no evidence of fracture of the femoral head or acetabulum which would be a contraindication for closed reduction; however, the prognosis for closed reduction is guarded owing to the dysplastic conformation of the hip joint and re-luxations are unfortunately common. Other therapeutic options that could be discussed now or in case of re-luxation are femoral head and neck ostectomy or open reduction and internal fixation.

REFERRING VET

Dr. Jennifer Todd

INVOICE

47675

DATE

10-5-21



PATIENT

Theo Bartosic

SPECIES

Feline

BREED

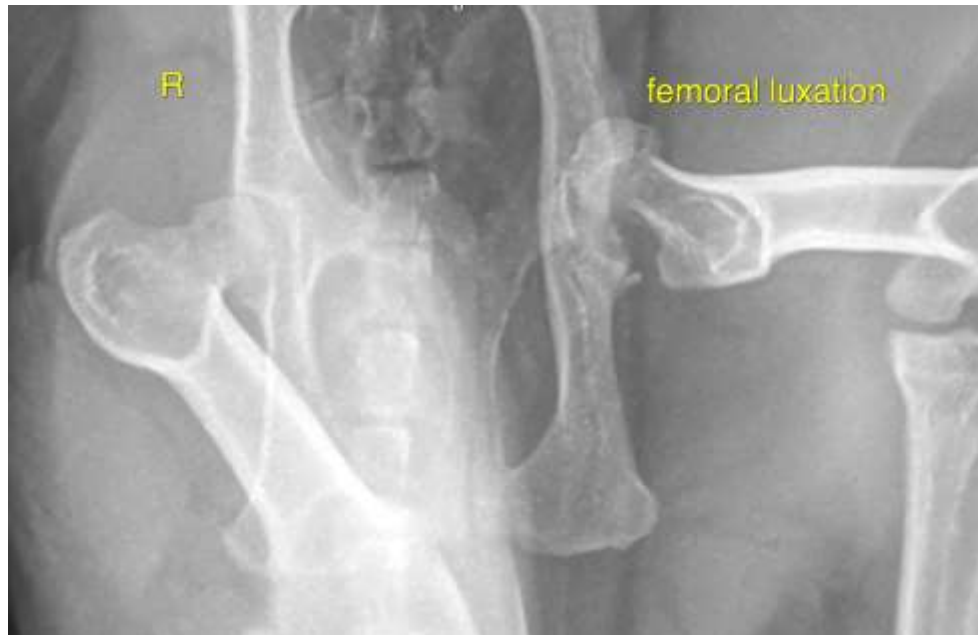
DSH

SEX

MN

AGE

7 Years



INTERPRETED BY

Nele Eley, DVM
Dr. med. Vet. DipECVDI

The information and recommendations provided are based on the images presented by the referring veterinarian. No evaluation can be communicated regarding pathology that was not visible in the image/video clips provided.

Thank you for this referral. If the clinical or image interpretation does not parallel your findings or if I can be of any further assistance please contact me.

HOSPITAL NAME

Lambs Gap Animal
Hospital

Nele Eley, DVM, Dr. med. vet., DipECVDI
European Specialist in Veterinary Diagnostic Imaging, Cert. Radiology,
Senior lecturer University of Giessen, Germany, Veterinary Faculty, Department of Radiology
Nele.Eley@sonopath.com

REFERRING VET

Dr. Jennifer Todd

INVOICE

47675

DATE

10-5-21