

**PATIENT**

Egor O'Brien

PRESENTING CLINICAL SIGNS

vomiting , bloody diarrhea , inappetence for 3 days
Abnormal PE/Chem/CBC/UA Results: mild elevation of ALT Significant elevation of ALP
Elevated WBCs Elevated GGT

SPECIES

Canine

RADIOGRAPHIC STUDY OF THE ABDOMEN

Right/left lateral and ventrodorsal views totaling 3 images available for review.

BREED

German Shepherd

RADIOGRAPHIC FINDINGS

There is mild lumbosacral and L6/7 spondyloses.

SEX

Male

No abnormalities of the extraabdominal soft tissues are noted. The abdominal wall is smooth and thin.

The serosal detail is maintained throughout the peritoneal and retroperitoneal space.

The liver is appropriate in position, size and presents uniform opacity.

AGE

6 Years

Generalized splenomegaly appears to be present and is suggestive for idiopathic German Shepherd dog hypersplenism.

INTERPRETED BY

Nele Eley, DVM
Dr. med. Vet. DipECVDI

Both kidneys are seen and present with normal size, shape, delineation and opacity. The urinary bladder is in its anticipated position. No radiopaque calculi are noted throughout the upper and lower urinary tract.

Moderate gastrointestinal aerophagia is seen.

HOSPITAL NAME

St. Catherine's Animal
Hospital

The small intestinal loops are evenly distributed throughout the mid abdomen. There is no evidence of abnormal dilation, plication, or foreign material. A moderate gas pattern with partially foamy appearance is noted throughout the small intestine. The cecum contains gas and is in its anticipated position.

The colon is mostly empty. No abnormal content or deviation of the colon is seen.

REFERRING VET

Dr. Boctor

RADIOGRAPHIC DIAGNOSIS

- Gastrointestinal maldigestion pattern - no evidence of mechanical ileus seen.

INVOICE

47686

INTERPRETATION OF THE FINDINGS & FURTHER RECOMMENDATIONS

The radiographic study is negative for mechanical ileus. The findings are suggestive for functional ileus. Subileus cannot be ruled out entirely. Consider further definition by means of ultrasound in case of persisting or deteriorating clinical signs.

DATE

10-5-21



PATIENT

Egor O'Brien

SPECIES

Canine

BREED

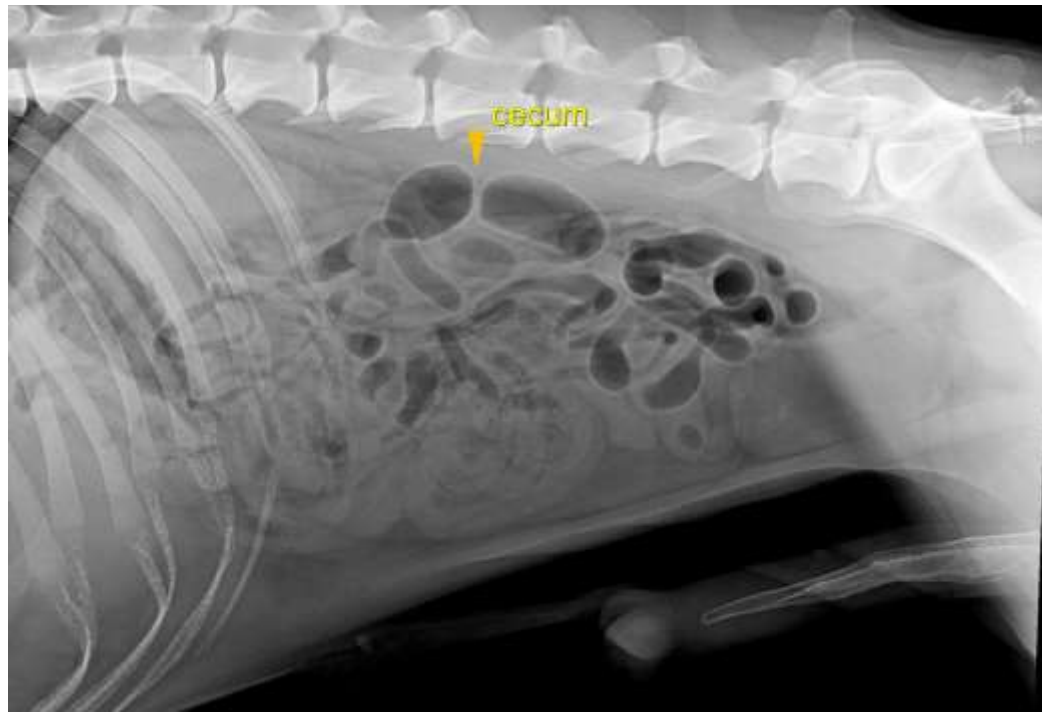
German Shepherd

SEX

Male

AGE

6 Years



INTERPRETED BY

Nele Eley, DVM
Dr. med. Vet. DipECVDI

The information and recommendations provided are based on the images presented by the referring veterinarian. No evaluation can be communicated regarding pathology that was not visible in the image/video clips provided.

Thank you for this referral. If the clinical or image interpretation does not parallel your findings or if I can be of any further assistance please contact me.

HOSPITAL NAME

St. Catherine's Animal
Hospital

Nele Eley, DVM, Dr. med. vet., DipECVDI
European Specialist in Veterinary Diagnostic Imaging, Cert. Radiology,
Senior lecturer University of Giessen, Germany, Veterinary Faculty, Department of Radiology
Nele.Eley@sonopath.com

REFERRING VET

Dr. Boctor

INVOICE

47686

DATE

10-5-21