

**PATIENT**

Allis Tadewaldt

PRESENTING CLINICAL SIGNS

Back end issues, perception loss for the last 2 months getting progressively worse.

SPECIES

Canine

RADIOGRAPHIC STUDY OF THE LUMBAR SPINE

Right/left lateral and ventrodorsal views of the lumbar spine totaling 5 images available for review.

BREED

Great Pyrenees

RADIOGRAPHIC FINDINGS

There is a symmetric lumbosacral transitional vertebra.

Motheaten osteolysis of the 6th lumbar vertebra is seen accentuating its vertebral body and blending into the vertebral arch as well. The cortical outline of the vertebral body of L6 is lost.**SEX**

Female Spayed

Moderate generalized decrease in bone opacity throughout the axial skeleton is noted.

AGE

11 Years

RADIOGRAPHIC DIAGNOSIS

- Monostotic aggressive osteolytic lesion of the 6th lumbar vertebra.
- Congenital lumbosacral transitional vertebra - incidental.
- Generalized osteopenia.

INTERPRETED BYNele Eley, DVM
Dr. med. Vet. DipECVDI**INTERPRETATION OF THE FINDINGS & FURTHER RECOMMENDATIONS**

The radiographic findings are highly suggestive for primary neoplasia of bone. Osteosarcoma, chondrosarcoma, or other mesenchymal neoplasia is likely. Metastatic disease of another primary tumor and lymphosarcoma as well as multiple myeloma are a theoretical potential as well. Unfortunately, the changes are in a nonresectable position and long term prognosis is poor.

HOSPITAL NAMEPacific Avenue
Veterinary Clinic**REFERRING VET**

Dr. Sid Bruckert- Frisk

INVOICE

47690

DATE

10-5-21



PATIENT

Allis Tadewaldt

SPECIES

Canine

BREED

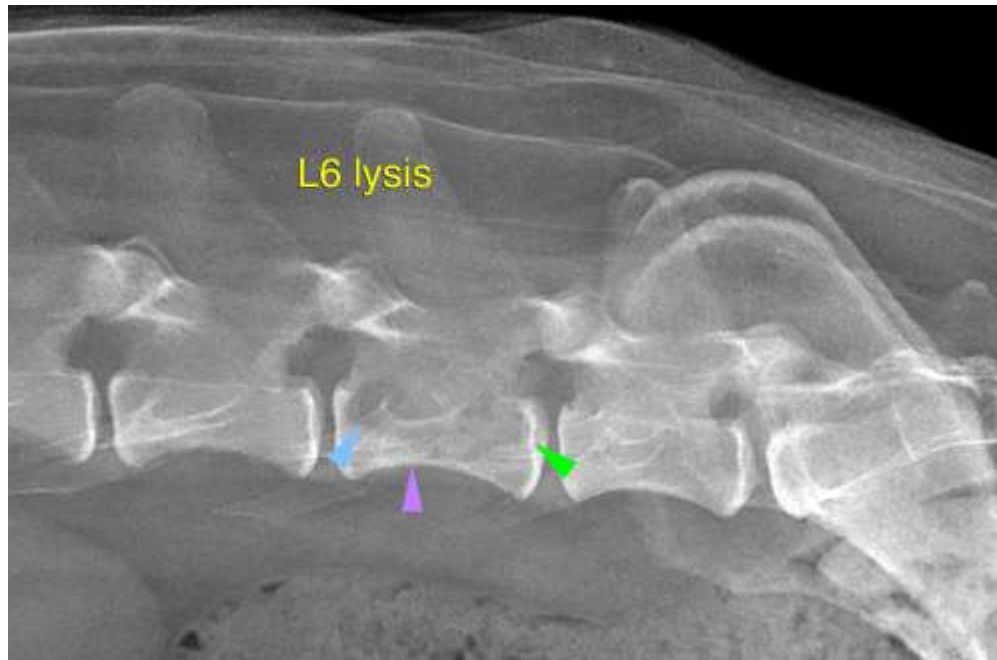
Great Pyrenees

SEX

Female Spayed

AGE

11 Years



INTERPRETED BY

Nele Eley, DVM
Dr. med. Vet. DipECVDI

The information and recommendations provided are based on the images presented by the referring veterinarian. No evaluation can be communicated regarding pathology that was not visible in the image/video clips provided.

Thank you for this referral. If the clinical or image interpretation does not parallel your findings or if I can be of any further assistance please contact me.

HOSPITAL NAME

Pacific Avenue
Veterinary Clinic

Nele Eley, DVM, Dr. med. vet., DipECVDI
European Specialist in Veterinary Diagnostic Imaging, Cert. Radiology,
Senior lecturer University of Giessen, Germany, Veterinary Faculty, Department of Radiology
Nele.Eley@sonopath.com

REFERRING VET

Dr. Sid Bruckert- Frisk

INVOICE

47690

DATE

10-5-21