



PATIENT

Rex Bivona

PRESENTING CLINICAL SIGNS

Pt presented for limping on/off on left front leg for about 6 months, but getting a little worse within the last month or so. Pt still running around normally, no signs of pain, but o noticing a limp. On PE: difficult to palpate due to pt being tense.

SPECIES

Canine

RADIOGRAPHIC STUDY OF THE LEFT ELBOW

Mediolateral neutral and flexed and craniocaudal views of the left elbow totaling 3 images available for review.

BREED

Australian Shepherd

RADIOGRAPHIC FINDINGS

The cranial contour of the medial coronoid process is mildly reduced in opacity and blurred.

SEX

Male Neutered

No significant subtrochlear notch sclerosis of the ulna can be seen.

There appears to be a mild radioulnar step formation.

AGE

3.5 Years

Thin double contours of the outline of the anconeus process and cranial contour of the radius are noted as well as mild roughening of the caudal contour of the lateral humeral epicondyle.

RADIOGRAPHIC DIAGNOSIS

- Minimal osteoarthritic changes of the left elbow.
- Mild blurring of the medial coronoid process in the left elbow.

INTERPRETED BY

Nele Eley, DVM
Dr. med. Vet. DipECVDI

INTERPRETATION OF THE FINDINGS & FURTHER RECOMMENDATIONS

The radiographic findings of the left elbow are minimal however medial coronoid pathology cannot be ruled out entirely with the noted radiographic changes and a CT study could be considered for further definition. Prior to that, radiographing the right elbow would be another option to obtain more information about the clinical significance of the noted changes.

HOSPITAL NAME

The Pet Hospital of
Stratford

Medial coronoid pathology is a rather uncommon underlying cause of clinical lameness in dogs of this breed and age and pathology in the shoulder such as the medial shoulder compartment, rotator cuff, or biceps are other theoretical considerations.

REFERRING VET

Dr. Claudia Giuliani,
DVM

INVOICE

54437

DATE

10-4-22



PATIENT

Rex Bivona

SPECIES

Canine

BREED

Australian Shepherd

SEX

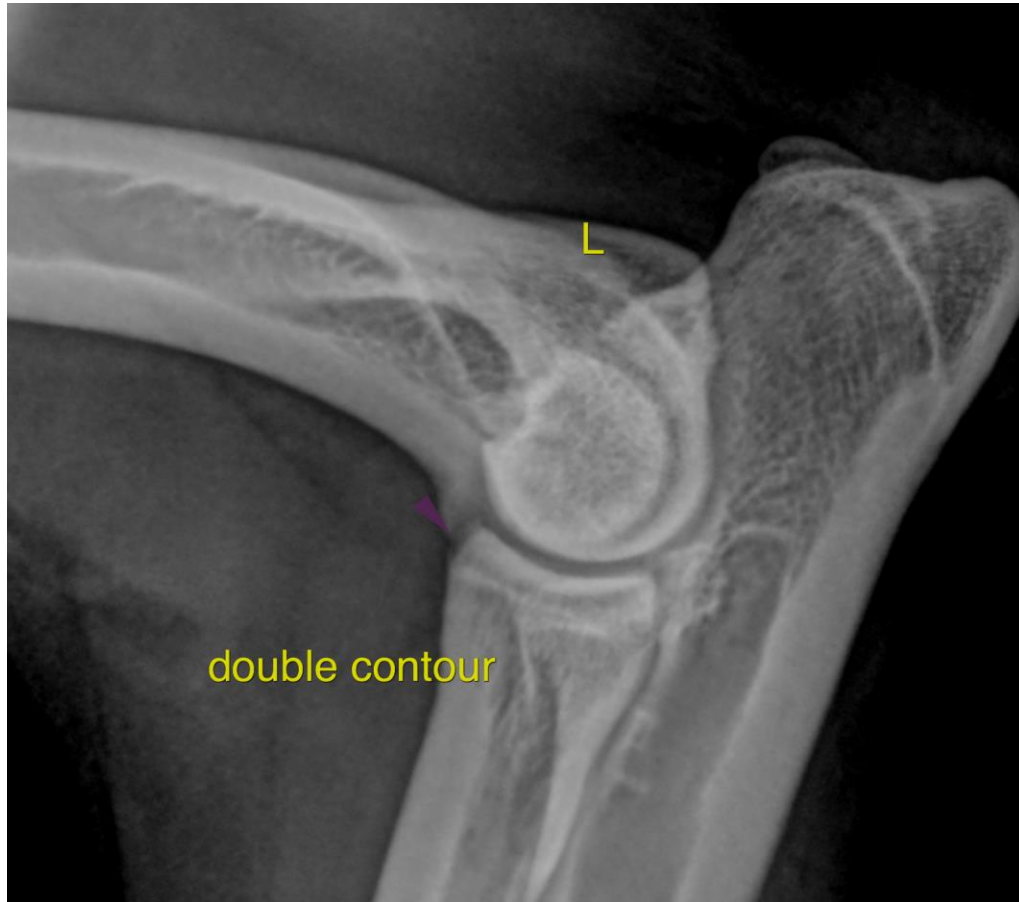
Male Neutered

AGE

3.5 Years

INTERPRETED BY

Nele Eley, DVM
Dr. med. Vet. DipECVDI



HOSPITAL NAME

The Pet Hospital of
Stratford

REFERRING VET

Dr. Claudia Giuliani,
DVM

INVOICE

54437

DATE

10-4-22

The information and recommendations provided are based on the images presented by the referring veterinarian/sonographer. No evaluation can be communicated regarding pathology that was not visible in the image/video clips provided.

Thank you for this referral. If the clinical or image interpretation does not parallel your findings or if I can be of any further assistance please contact me.

Nele Eley, DVM, Dr. med. vet., DipECVDI
European Specialist in Veterinary Diagnostic Imaging, Cert. Radiology,
Senior lecturer University of Giessen, Germany, Veterinary Faculty, Department of Radiology
Nele.Eley@sonopath.com