

**PATIENT**

Maeve Farlow

SPECIES

Feline

BREED

DSH

SEX

FS

AGE

6 Years

INTERPRETED BYNele Eley, DVM
Dr. med. Vet. DipECVDI**HOSPITAL NAME**Wellington Animal
Hospital**REFERRING VET**

Dr.Elizabeth Dennis

INVOICE

54434

DATE

10-4-22

PRESENTING CLINICAL SIGNS

For the past 2 weeks has been hiding more than normal Diarrhea started on the weekend along with decreased appetite Noted to have abnormal breathing periodically at home
Abnormal PE/Chem/CBC/UA Results: Painful on cranial abdominal palpation Intermittent abdominal effort with breathing Hydration borderline (slight skin tent) BW and urine are still pending Maeve was originally adopted through a rescue so her age was a best guess.

RADIOGRAPHIC STUDY OF THE THORAX

Right/left lateral and ventrodorsal views of the thorax totaling 3 images available for review.

RADIOGRAPHIC FINDINGS

The degree of pulmonary inflation is fair on the available images. A mild to moderate generalized bronchial lung pattern with mild peribronchial cuffing is seen.

Course and width of the trachea are considered within normal limits.

There is no radiographic evidence of cardiovascular pathology or mediastinal widening. The vertebral heart score is 7.5.

The thoracic boundaries present within normal limits.

RADIOGRAPHIC DIAGNOSIS

- Mild to moderate bronchial lung pattern

INTERPRETATION OF THE FINDINGS & FURTHER RECOMMENDATIONS

The radiographic study reveals a mild to moderate bronchial lung pattern. No radiographic evidence of cardiovascular pathology is seen. differential diagnosis includes allergic lower airway syndrome as well as infectious bronchitis including viral, bacterial, parasitic, and protozoal. A clinical trial of treatment for feline asthma could be considered in case of coexisting clinical signs and as an alternative to direct airway endoscopy with airway sampling.



PATIENT

Maeve Farlow

SPECIES

Feline

BREED

DSH

SEX

FS

AGE

6 Years

INTERPRETED BY

Nele Eley, DVM
Dr. med. Vet. DipECVDI

HOSPITAL NAME

Wellington Animal
Hospital

REFERRING VET

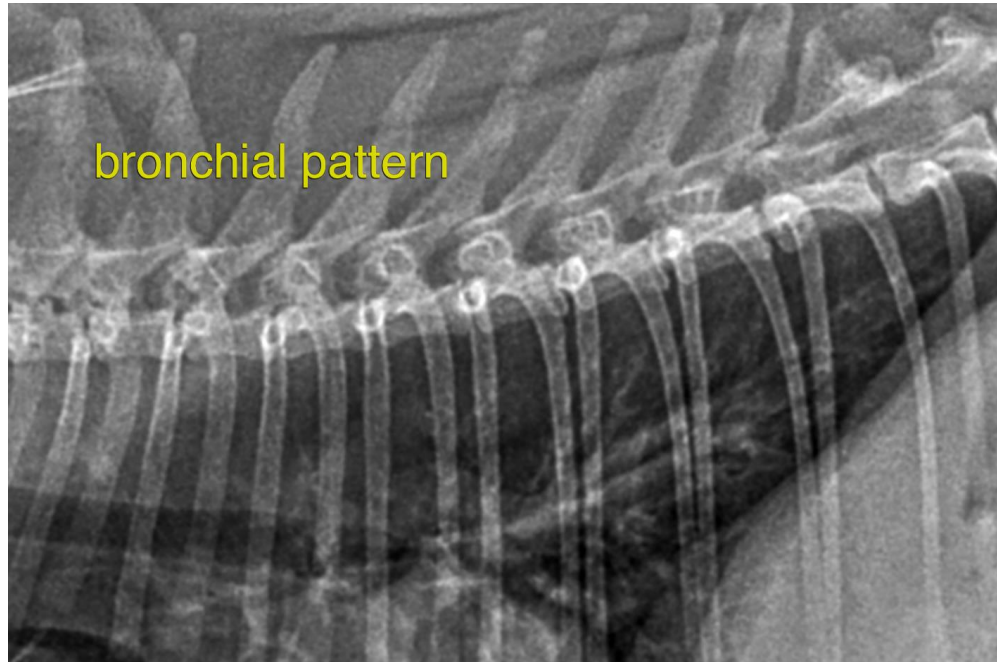
Dr.Elizabeth Dennis

INVOICE

54434

DATE

10-4-22



The information and recommendations provided are based on the images presented by the referring veterinarian/sonographer. No evaluation can be communicated regarding pathology that was not visible in the image/video clips provided.

Thank you for this referral. If the clinical or image interpretation does not parallel your findings or if I can be of any further assistance please contact me.

Nele Eley, DVM, Dr. med. vet., DipECVDI
European Specialist in Veterinary Diagnostic Imaging, Cert. Radiology,
Senior lecturer University of Giessen, Germany, Veterinary Faculty, Department of Radiology
Nele.Eley@sonopath.com