



**PATIENT PRESENTING CLINICAL SIGNS**

Minnie Dehnke Hx of hind limb ataxia that was acute in onset in March. Now doesn't seem to know when she needs to urinate or defecate - Will urinate/defecate out of litterbox (has diarrhea of unknown duration)

**SPECIES** Abnormal PE/Chem/CBC/UA Results: Bloodwork pending Urinalysis unremarkable  
 Decreased CP in both hind feet - will scuff them on the floor when walking Walks in a "crouched posture" in the hind limbs Not grooming caudal dorsal trunk or perineal region  
 Fe

**RADIOGRAPHIC STUDY OF THE THORACIC & LUMBAR SPINE**

**BREED** Lateral and ventrodorsal views of the thoracolumbar spine totaling 6 images available for review.  
 DSH

**RADIOGRAPHIC FINDINGS**

**SEX** Degenerative lumbosacral stenosis with moderately collapsed intervertebral disc space, vertebral end plate sclerosis, and spondylosis deformans are seen.

MS Mild spondyloses are present at L6/7 and L2/3.

**AGE** Moderate spondylosis is present at L1/2.

13 Multiple mild spondyloses are present throughout the mid and caudal thoracic spine with moderate spondyloses between T11/12 and T12/13.

**INTERPRETED BY** The cervical spine presents within age related normal limits.

Nele Eley, DVM  
 Dr. med. Vet. DipECVDI

**RADIOGRAPHIC DIAGNOSIS**

- Moderate degenerative lumbosacral stenosis.
- Multiple thoracolumbar spondyloses.

**HOSPITAL NAME**

Torch Lake  
 Veterinary Clinic

**INTERPRETATION OF THE FINDINGS & FURTHER RECOMMENDATIONS**

The radiographic study reveals no evidence of aggressive bone lesions or traumatic osseous injury. Multiple spondyloses are seen which may be associated with intervertebral disc disease. There is moderate degenerative lumbosacral stenosis with moderate collapse of the intervertebral disc space which may be associated with disc hernia. Further evaluation for compressive or other myelopathy / cauda equina compression requires cross sectional imaging, an MRI would be ideal in this patient, depending on the severity and development of the clinical signs.

**REFERRING VET**

Adrienne Waffle

**INVOICE**

47654

**DATE**

10-4-21



**PATIENT**

Minnie Dehnke

**SPECIES**

Fe

**BREED**

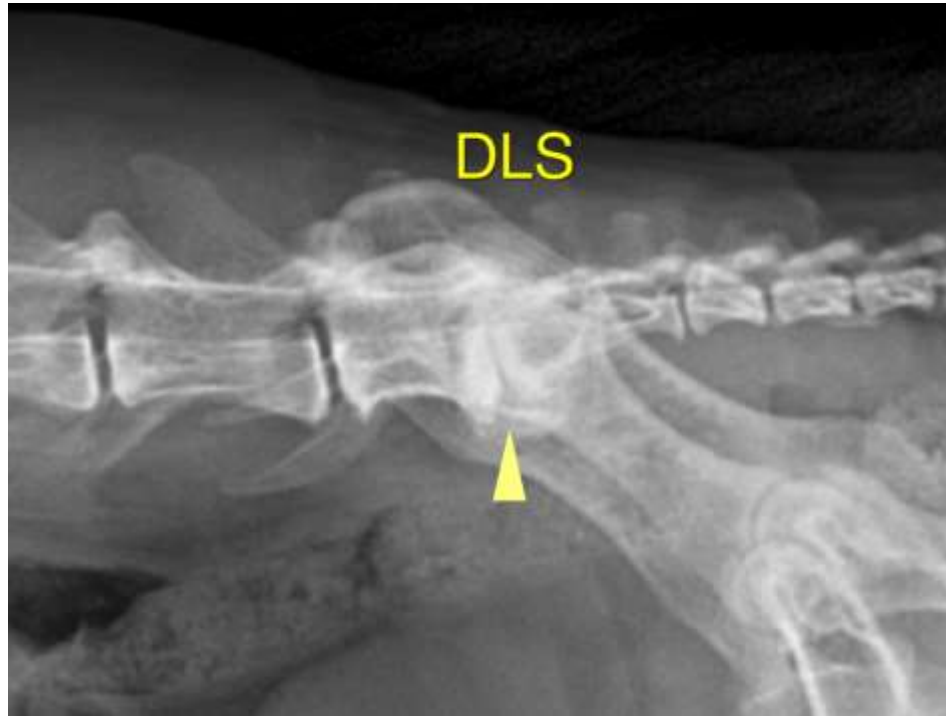
DSH

**SEX**

MS

**AGE**

13



**INTERPRETED BY**

Nele Eley, DVM  
Dr. med. Vet. DipECVDI

The information and recommendations provided are based on the images presented by the referring veterinarian. No evaluation can be communicated regarding pathology that was not visible in the image/video clips provided.

Thank you for this referral. If the clinical or image interpretation does not parallel your findings or if I can be of any further assistance please contact me.

**HOSPITAL NAME**

Torch Lake  
Veterinary Clinic

**Nele Eley**, DVM, Dr. med. vet., DipECVDI  
European Specialist in Veterinary Diagnostic Imaging, Cert. Radiology,  
Senior lecturer University of Giessen, Germany, Veterinary Faculty, Department of Radiology  
Nele.Eley@sonopath.com

**REFERRING VET**

Adrienne Waffle

**INVOICE**

47654

**DATE**

10-4-21