



**PATIENT**

Copper Brewer

**PRESENTING CLINICAL SIGNS**

hx hematuria. Resolved on antibiotics. Loosing weight. O says painful in the hind end, cries when touched. Favoring RH.  
Abnormal PE/Chem/CBC/UA Results: UA 5+ WBC. Bloodwork pending. Painful on rectal, even while sedated.

**SPECIES**

Canine

**RADIOGRAPHIC STUDY OF THE CAUDAL ABDOMEN**

Right/left lateral and ventrodorsal views totaling 3 images available for review.

**BREED**

Husky

**RADIOGRAPHIC FINDINGS**

Moderate prostatomegaly is seen. The prostate measures approximately 5.0 cm in diameter and occupies 60% of the pelvic inlet. No significant dorsal deviation of the colon is seen. The periprostatic fat is well delineated.

**SEX**

Intact Male

The urinary bladder is moderately distended. No abnormal opacities are seen throughout the prostate and urinary bladder.

**AGE**

7 Years

There is no radiographic evidence of sublumbar lymphadenomegaly.

There appears to be moderate intestinal aerophagia.

**INTERPRETED BY**

Nele Eley, DVM  
Dr. med. Vet. DipECVDI

The radiographic presentation of the caudal lumbar spine and lumbosacral junction is within normal limits.

Mild spondylosis and vertebral end plate sclerosis is noted at L2/3 and L1/2.

The coxofemoral joints present within normal limits.

**HOSPITAL NAME**

Pinebrook Animal  
Hospital

**RADIOGRAPHIC DIAGNOSIS**

- Moderate prostatomegaly.

**REFERRING VET**

Dr. Britt Dubil

**INTERPRETATION OF THE FINDINGS & FURTHER RECOMMENDATIONS**

The prostatic enlargement may be due to benign prostatic hyperplasia of the non-neutered male; however, based on the painful rectal palpation in the clinical history of the patient, prostatitis and neoplastic infiltrates should be considered as well as underlying causes of the organomegaly. Consider further definition by means of ultrasound with eventual ultrasound guided sampling. Full urinalysis could be considered in the patient's further workup as well if not performed already.

**INVOICE**

47670

**DATE**

10-4-21



**PATIENT**

Copper Brewer

**SPECIES**

Canine

**BREED**

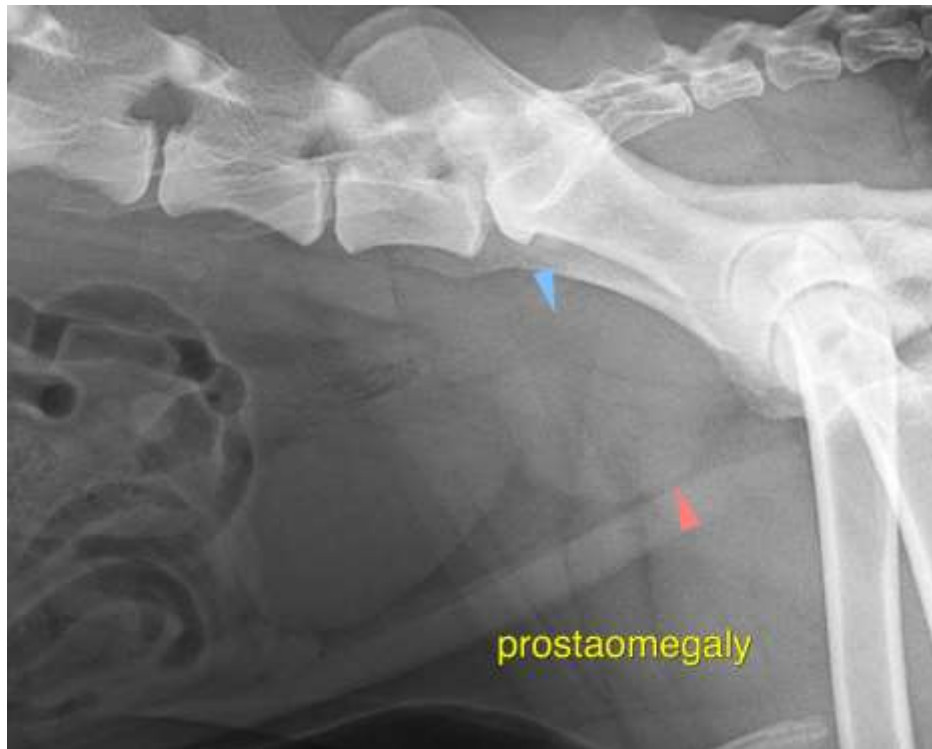
Husky

**SEX**

Intact Male

**AGE**

7 Years



**INTERPRETED BY**

Nele Eley, DVM  
Dr. med. Vet. DipECVDI

The information and recommendations provided are based on the images presented by the referring veterinarian. No evaluation can be communicated regarding pathology that was not visible in the image/video clips provided.

**HOSPITAL NAME**

Pinebrook Animal  
Hospital

Thank you for this referral. If the clinical or image interpretation does not parallel your findings or if I can be of any further assistance please contact me.

**REFERRING VET**

Dr. Britt Dubil

**Nele Eley**, DVM, Dr. med. vet., DipECVDI  
European Specialist in Veterinary Diagnostic Imaging, Cert. Radiology,  
Senior lecturer University of Giessen, Germany, Veterinary Faculty, Department of Radiology  
Nele.Eley@sonopath.com

**INVOICE**

47670

**DATE**

10-4-21