



**PATIENT**

Toba Dixon

**PRESENTING CLINICAL SIGNS**

Was at boarding kennel last week, two nights ago he was at dog park and had a short altercation with another dog and has been favouring right front leg since. Suspect shoulder injury. U/S shoulder

**SPECIES**

Canine

Abnormal PE/Chem/CBC/UA Results: 1. Suspicion of osteochondrosis of the caudal aspect of the humeral head of the right shoulder. 2. Otherwise unremarkable right forelimb. 3. Unremarkable left forelimb. 4. Mild right-sided cardiomegaly. Taurine Plasma levels = 151 (N 60-120) BNP 689 (N 0-900)

**BREED**

Lab

**ULTRASONOGRAPHIC FINDINGS**

**Right Shoulder**

The right supraspinatus tendon measures 8mm in thickness, is well delineated, and of uniform internal echoarchitecture. The attachment to the greater humeral tubercle is smooth. There is no evidence of biceps impingement. The biceps tendon presents no evidence of echoarchitectural changes and is well delineated. A moderate amount of anechoic effusion is seen in the biceps tendon sheath. Mild generalized thickening of its synovium is noted. Occasional hyperechoic foci are seen within the anechoic fluid and there is a mild amount of smooth new bone formation in the intertubercular groove.

**SEX**

MN

**AGE**

1 Year, 9 Months

**ULTRASONOGRAPHIC DIAGNOSIS**

- Mild right biceps tenosynovitis and suspect translocation of effusion from the right shoulder joint.

**INTERPRETED BY**

Nele Eley, DVM  
Dr. med. Vet. DipECVDI

**INTERPRETATION OF THE FINDINGS & FURTHER RECOMMENDATIONS**

The ultrasonographic findings support the presence of mild chronic right biceps tenosynovitis. The degree of effusion exceeds the degree of synovial swelling and remainder of architectural changes so that secondary tenosynovitis due to shoulder osteochondritis appears to be a valid tentative diagnosis that would explain the ultrasonographic changes within the biceps tendon and intertubercular groove in this patient. A dissecate was not seen within the biceps tendon sheath.

**HOSPITAL NAME**

Westview Veterinary  
Hospital

**REFERRING VET**

Dr. Brian Barnes

**INVOICE**

54881

**DATE**

10-31-22



**PATIENT**

Toba Dixon

**SPECIES**

Canine

**BREED**

Lab

**SEX**

MN

**AGE**

1 Year, 9 Months

**INTERPRETED BY**

Nele Eley, DVM  
Dr. med. Vet. DipECVDI

**HOSPITAL NAME**

Westview Veterinary  
Hospital

**REFERRING VET**

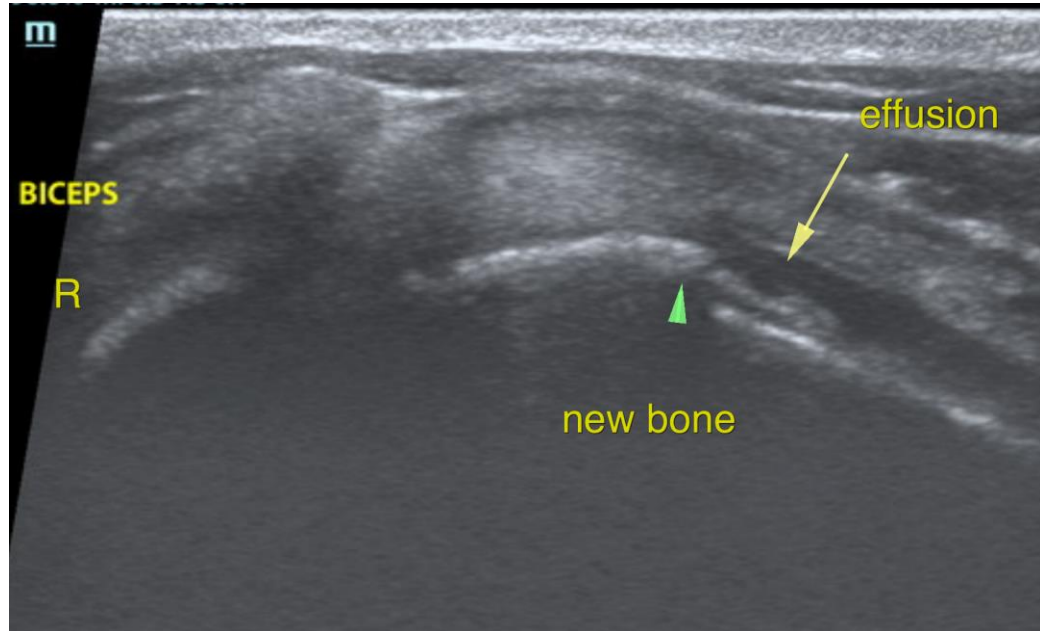
Dr. Brian Barnes

**INVOICE**

54881

**DATE**

10-31-22



The information and recommendations provided are based on the images presented by the referring veterinarian/sonographer. No evaluation can be communicated regarding pathology that was not visible in the image/video clips provided.

Thank you for this referral. If the clinical or image interpretation does not parallel your findings or if I can be of any further assistance please contact me.

**Nele Eley**, DVM, Dr. med. vet., DipECVDI  
European Specialist in Veterinary Diagnostic Imaging, Cert. Radiology,  
Senior lecturer University of Giessen, Germany, Veterinary Faculty, Department of Radiology  
Nele.Eley@sonopath.com