

**PATIENT**

Tucker Eadie

**PRESENTING CLINICAL SIGNS**

\*\* Recheck Case \*\* These are follow up radiographs taken today for "Tucker" Eadie. Initial case was sent on Oct 4th, 2021 which Dr. Eley interpreted post hit by car. Tucker is doing well at home with no concerns. Looking for any abnormalities seen at this stage. Thank you.

**SPECIES**

Canine

**RADIOGRAPHIC STUDY OF THE THORAX**

Right/left lateral and ventrodorsal views totaling 4 images available for review. Compared to prior study dated 10-4.

**BREED**

Labrador Retriever

**RADIOGRAPHIC FINDINGS**

Patient has a history of car accident with pneumothorax and pulmonary bullae.

**SEX**

Male Neutered

No evidence of residual air is seen in the pleural space or mediastinum.

The peripheral mixed infiltrate within the ventral aspect of the cranial lung lobes has resolved and is no longer visible.

**AGE**

7 Years, 9 Months

Minimal remnants of the cavitory lesions within the caudodorsal lung are still seen.

The soft tissue opaque round lesion dorsal of the heart base is no longer visible.

**INTERPRETED BY**

Nele Eley, DVM  
Dr. med. Vet. DipECVDI

**RADIOGRAPHIC DIAGNOSIS**

- Full regression of the pulmonary infiltrate.
- Regression of the presumed hemothorax in the caudal lung field.
- Complete remission of the pneumothorax.

**HOSPITAL NAME**

East Credit  
Veterinary Hospital

**INTERPRETATION OF THE FINDINGS & FURTHER RECOMMENDATIONS**

Minimal remnants of the thin walls of the cavitory lesions in the caudodorsal aspect of the lung appear to be present; however, there is no evidence of gas filled cavities and the round smaller lesion level with the heart base has resolved completely. The findings are within the expected limits and a radiographic recheck would only be indicated in case of clinical signs such as respiratory distress.

**REFERRING VET**

Wendy Webster

**INVOICE**

48053

**DATE**

10-27-21



**PATIENT**

Tucker Eadie

**SPECIES**

Canine

**BREED**

Labrador Retriever

**SEX**

Male Neutered

**AGE**

7 Years, 9 Months

**INTERPRETED BY**

Nele Eley, DVM  
Dr. med. Vet. DipECVDI

**HOSPITAL NAME**

East Credit  
Veterinary Hospital

**REFERRING VET**

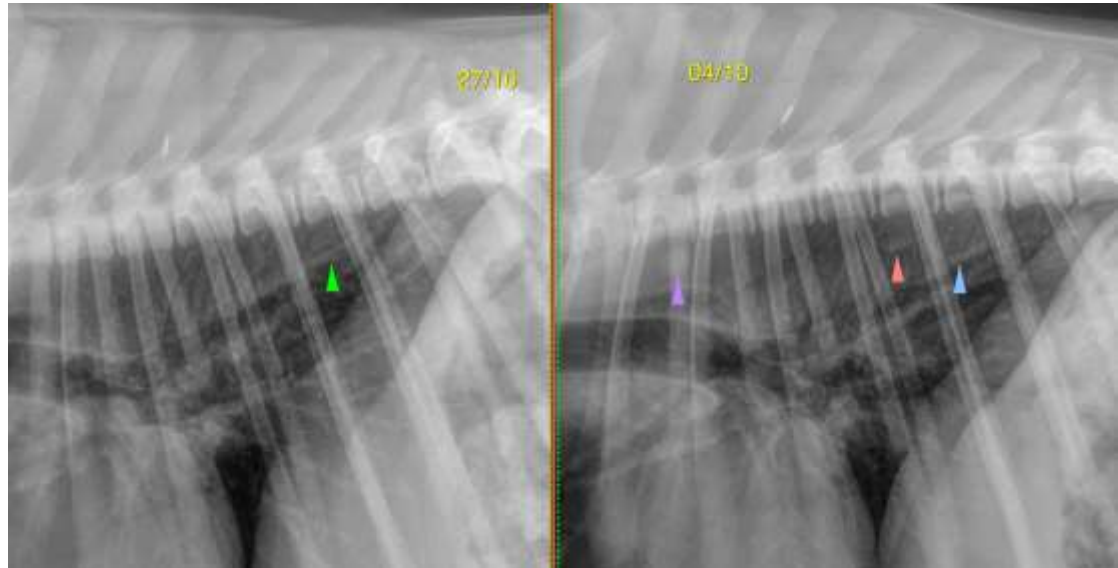
Wendy Webster

**INVOICE**

48053

**DATE**

10-27-21



The information and recommendations provided are based on the images presented by the referring veterinarian. No evaluation can be communicated regarding pathology that was not visible in the image/video clips provided.

Thank you for this referral. If the clinical or image interpretation does not parallel your findings or if I can be of any further assistance please contact me.

**Nele Eley**, DVM, Dr. med. vet., DipECVDI  
European Specialist in Veterinary Diagnostic Imaging, Cert. Radiology,  
Senior lecturer University of Giessen, Germany, Veterinary Faculty, Department of Radiology  
Nele.Eley@sonopath.com