

**PATIENT**

Muneca Beck

**PRESENTING CLINICAL SIGNS**

Walks with head down, significant pain when turning head to the left. Is taking Gabapentin, Rimadyl and Methocarbamol. Recently developed inappetence, but ate normal breakfast this morning.

**SPECIES**

Canine

**COMPUTED TOMOGRAPHIC STUDY OF THE CERVICAL SPINE**

Plain and post IV contrast studies available for review.

**BREED**

Pitbull Mix

**COMPUTED TOMOGRAPHIC FINDINGS**

Moderate narrowing of the intervertebral disc space C3/4 is seen. There is extrusion of mineral attenuating material into the ventral epidural space over the intervertebral disc space C3/4 with cranial migration and leftward shift within the ventral epidural space. Most of the material is situated over the caudal vertebral end plate of C3. Approximately 60% of the vertebral canal's cross sectional area are occupied by the extruded mineral attenuating material. Moderate to severe rightward and dorsal deviation of the spinal cord is seen.

**SEX**

Female Spayed

Partial mineralization of the intervertebral disc T2/3 is present.

**AGE**

10 Years

**COMPUTED TOMOGRAPHIC DIAGNOSIS**

- Lateralized intervertebral disc extrusion with cranial migration and severe spinal cord compression within the cervical spine at C3/4.
- Chondroid disc degeneration.

**INTERPRETED BY**

Nele Eley, DVM  
Dr. med. Vet. DipECVDI

**INTERPRETATION OF THE FINDINGS & FURTHER RECOMMENDATIONS**

Moderate to severe compression of the spinal cord due to extrusion of mineralized intervertebral disc material is seen within the craniocervical spine at C3/4. The largest volume of the extrusion is situated over the caudal end of the 3<sup>rd</sup> cervical vertebra and shifted towards the left of the midline within the ventral epidural space. Based on the volume of the extrusion and compression of the spinal cord, decompressive surgery appears to be indicated.

**HOSPITAL NAME**

Parrish Creek  
Veterinary Clinic

**REFERRING VET**

Megan Goodnight,  
DVM

**INVOICE**

48055

**DATE**

10-27-21



**PATIENT**

Muneca Beck

**SPECIES**

Canine

**BREED**

Pitbull Mix

**SEX**

Female Spayed

**AGE**

10 Years

**INTERPRETED BY**

Nele Eley, DVM  
Dr. med. Vet. DipECVDI

**HOSPITAL NAME**

Parrish Creek  
Veterinary Clinic

**REFERRING VET**

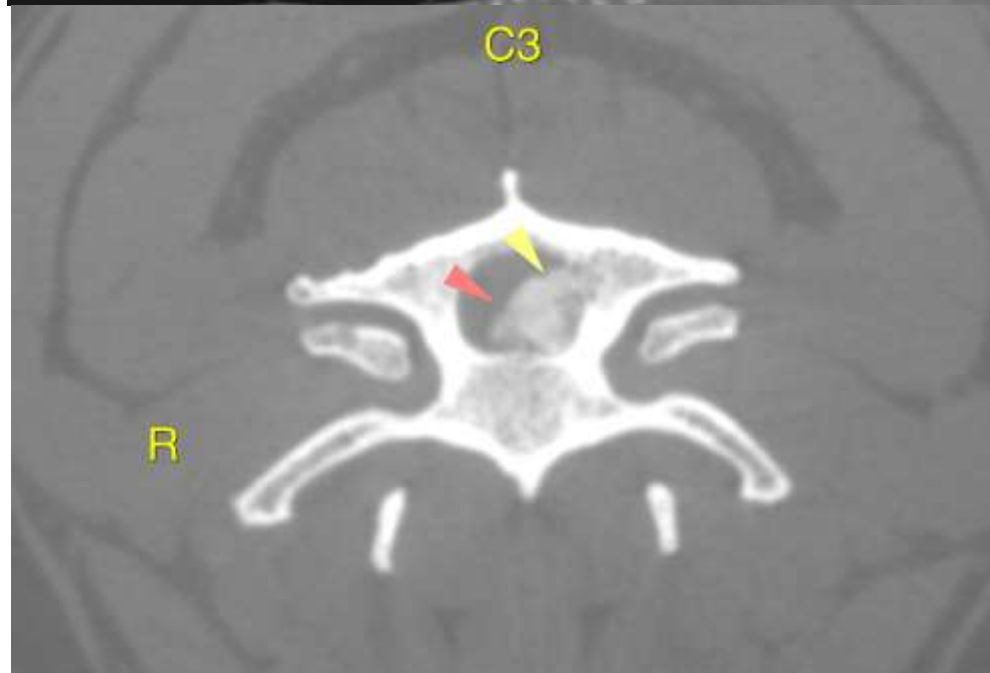
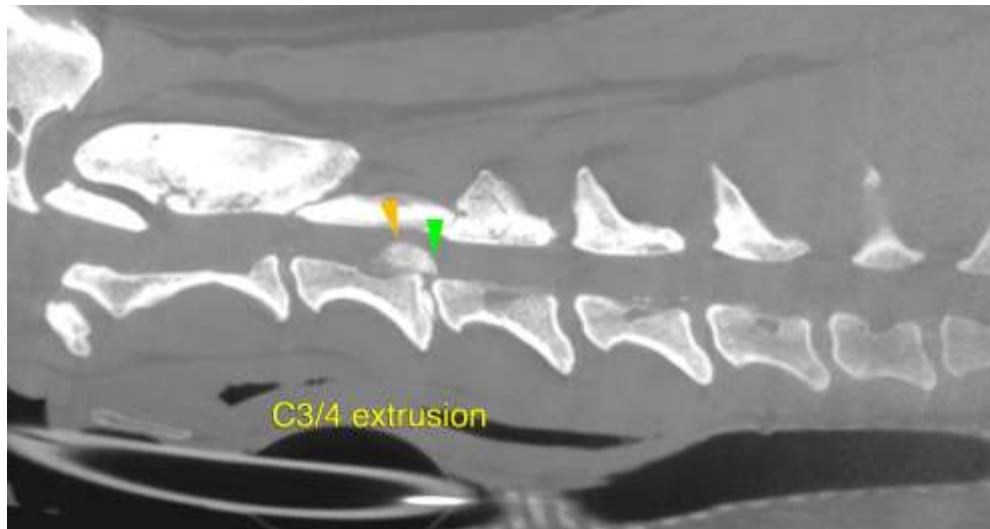
Megan Goodnight,  
DVM

**INVOICE**

48055

**DATE**

10-27-21



The information and recommendations provided are based on the images presented by the referring veterinarian. No evaluation can be communicated regarding pathology that was not visible in the image/video clips provided.

Thank you for this referral. If the clinical or image interpretation does not parallel your findings or if I can be of any further assistance please contact me.

**Nele Eley**, DVM, Dr. med. vet., DipECVDI  
European Specialist in Veterinary Diagnostic Imaging, Cert. Radiology,  
Senior lecturer University of Giessen, Germany, Veterinary Faculty, Department of Radiology  
Nele.Eley@sonopath.com