

**PATIENT**

Chloe Fuchs

PRESENTING CLINICAL SIGNS

Patient presented for vomiting and diarrhea for about 2 weeks, in house CPL >690, positive

SPECIES

Canine

RADIOGRAPHIC STUDY OF THE ABDOMEN

Right/left lateral and ventrodorsal views totaling 3 images available for review.

BREED

Pitbull Terrier

RADIOGRAPHIC FINDINGS

The patient is mildly obese.

Severe L1/2 spondylosis deformans is seen.

The ventral abdominal wall is mildly pendulous.

SEX

FS

The serosal detail is maintained throughout the peritoneal and retroperitoneal space.

The liver is appropriate in position, size and presents uniform opacity.

AGE

11.6 Years

The splenic head is in the anticipated position and within normal limits for size and opacity. The splenic body and tail are considered normal for position, size, shape and opacity.

Both kidneys are seen and present with normal size, shape, delineation and opacity. The urinary bladder is in its anticipated position. No radiopaque calculi are noted throughout the upper and lower urinary tract.

INTERPRETED BYNele Eley, DVM
Dr. med. Vet. DipECVDI

There is moderate gastric aerophagia.

The small intestinal loops are evenly distributed throughout the mid abdomen. There is no evidence of abnormal dilation. However, predominance of a gas pattern and turgid appearance of the small intestine is noted.

HOSPITAL NAMEBoca Park Animal
Hospital

The large intestine is mostly empty.

RADIOGRAPHIC DIAGNOSIS

- Gastrointestinal maldigestion pattern.
- Obesity with pendulous ventral abdominal wall.

REFERRING VET

Dr. Corinna Gorgon

INTERPRETATION OF THE FINDINGS & FURTHER RECOMMENDATIONS**INVOICE**

48039

The radiographic findings are suggestive for functional ileus which may well be associated with pancreatopathy or gastroenteropathy. No evidence of mechanical ileus is evident radiographically. Depending on the patient's response to the initiated management, completing the workup by means of full abdominal ultrasound could be considered.

DATE

10-27-21



PATIENT

Chloe Fuchs

SPECIES

Canine

BREED

Pitbull Terrier

SEX

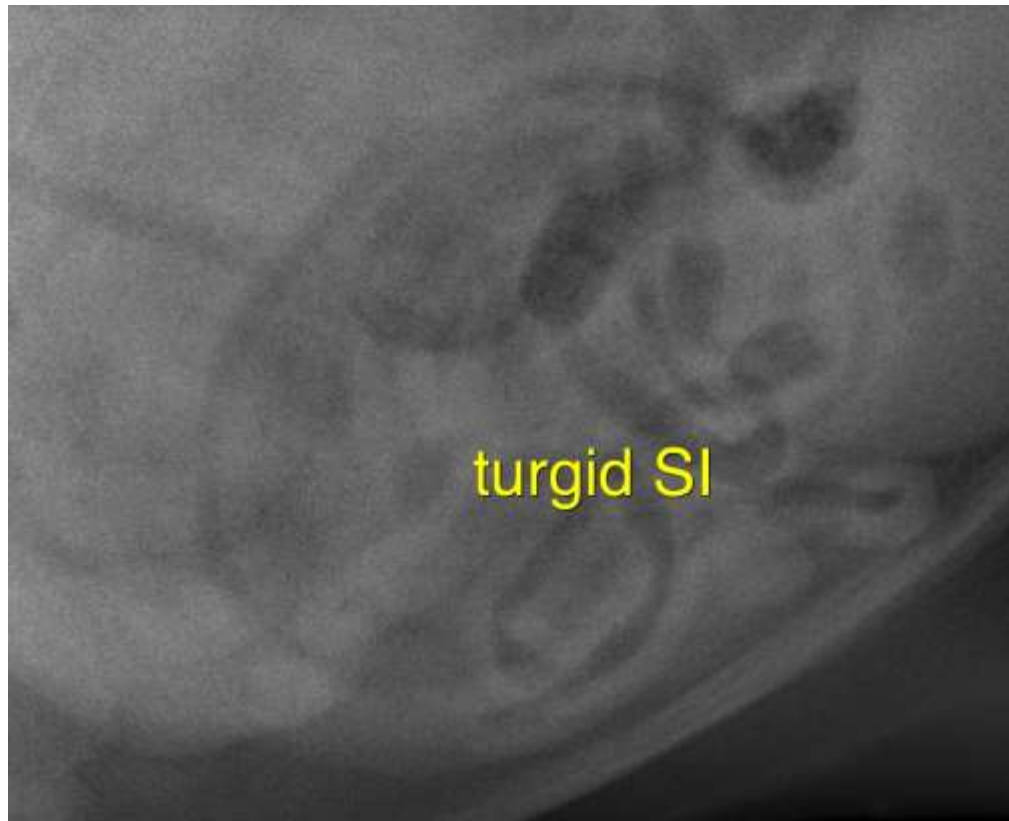
FS

AGE

11.6 Years

INTERPRETED BY

Nele Eley, DVM
Dr. med. Vet. DipECVDI



HOSPITAL NAME

Boca Park Animal
Hospital

REFERRING VET

Dr. Corinna Gorgon

INVOICE

48039

DATE

10-27-21

The information and recommendations provided are based on the images presented by the referring veterinarian. No evaluation can be communicated regarding pathology that was not visible in the image/video clips provided.

Thank you for this referral. If the clinical or image interpretation does not parallel your findings or if I can be of any further assistance please contact me.

Nele Eley, DVM, Dr. med. vet., DipECVDI
European Specialist in Veterinary Diagnostic Imaging, Cert. Radiology,
Senior lecturer University of Giessen, Germany, Veterinary Faculty, Department of Radiology
Nele.Eley@sonopath.com