



**PATIENT**

Cubby Ingrassia

**PRESENTING CLINICAL SIGNS**

Patient with history of proteinuria presents due to right hind lameness x 2.5 months. Medial buttress RH. History of colitis, now hematochezia. (abdominal ultrasound performed as well). Current meds: Galliprant 60 mgs SID, Apoquel 16 mgs BID, Enalapril 20 mgs BID. Abnormal PE/Chem/CBC/UA Results: CBC/Chem: pending. U/A: pending.

**SPECIES**

Canine

**ULTRASONOGRAPHIC FINDINGS**

**Right Stifle**

A large amount of anechoic effusion is seen within the supra- and infra-patellar recesses of the right stifle joint. The synovial sheath of the long digital extensor tendon which communicates with the stifle joint contains a moderate amount of anechoic effusion as well. There is severe thickening of the synovium and joint capsule.

**BREED**

Labrador Retriever

**SEX**

MN

The right cranial cruciate ligament presents as an echoic stump surrounded by a halo of anechoic effusion at the intercondylar eminence of the tibia.

The visible parts of the lateral and medial meniscus present in situ and within normal limits.

**AGE**

7 Years

Osteophytes are seen at the periarticular margins of the femoral tibia and femoral patella joints.

**Left Stifle**

Mild effusion and mild synovial swelling are noted within the left stifle joint.

The cranial cruciate ligament is continuous, yet it appears to be slightly ill-defined and thickened. Heterogeneity of the infrapatellar fat pad is noted.

The visible parts of the lateral and medial meniscus present within normal limits.

**INTERPRETED BY**

Nele Eley, DVM  
Dr. med. Vet. DipECVDI

**ULTRASONOGRAPHIC DIAGNOSIS**

- Moderate to severe osteoarthritis of the right stifle joint with ruptured cranial cruciate ligament.
- Suspect edema and mild osteoarthritis of the left stifle joint.

**HOSPITAL NAME**

Our House Call Vet

**REFERRING VET**

Dr. Mazzola

**INTERPRETATION OF THE FINDINGS & FURTHER RECOMMENDATIONS**

The ultrasonographic findings are compatible with a fully ruptured cranial cruciate ligament in the right stifle. Moderate to severe concurrent osteoarthritis with extensive synovitis is seen.

**INVOICE**

54836

The findings of the left stifle joint support presence of degenerative joint disease with mild osteoarthritis and edema of the cranial cruciate ligament. Incipient fiber disintegration of the cruciate ligament in terms of an early partial rupture of the left cranial cruciate ligament cannot be ruled out entirely.

**DATE**

10-26-22



**PATIENT**

Cubby Ingrassia

**SPECIES**

Canine

**BREED**

Labrador Retriever

**SEX**

MN

**AGE**

7 Years

**INTERPRETED BY**

Nele Eley, DVM  
Dr. med. Vet. DipECVDI

**HOSPITAL NAME**

Our House Call Vet

**REFERRING VET**

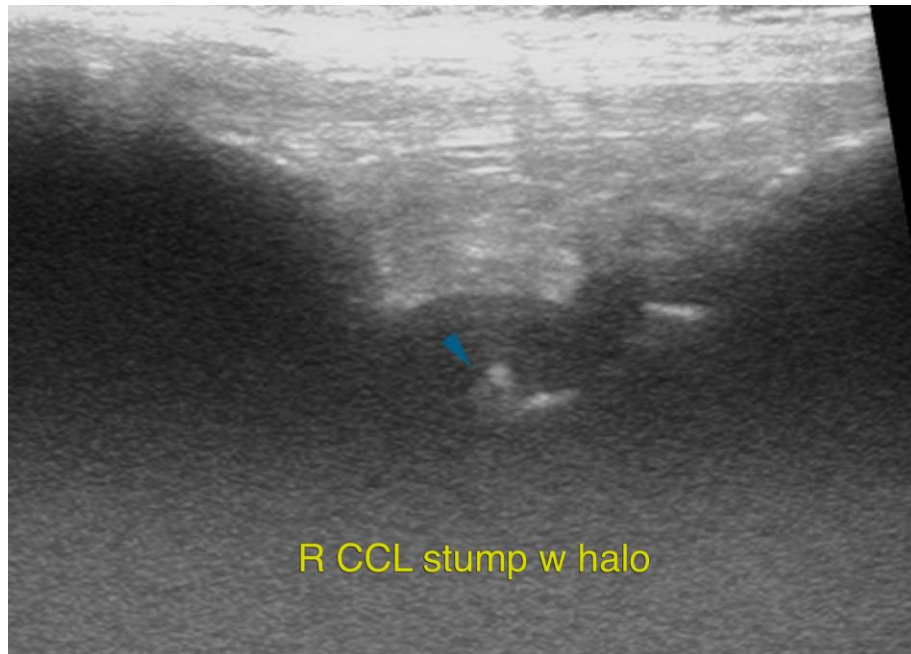
Dr. Mazzola

**INVOICE**

54836

**DATE**

10-26-22



The information and recommendations provided are based on the images presented by the referring veterinarian/sonographer. No evaluation can be communicated regarding pathology that was not visible in the image/video clips provided.

Thank you for this referral. If the clinical or image interpretation does not parallel your findings or if I can be of any further assistance please contact me.

**Nele Eley**, DVM, Dr. med. vet., DipECVDI  
European Specialist in Veterinary Diagnostic Imaging, Cert. Radiology,  
Senior lecturer University of Giessen, Germany, Veterinary Faculty, Department of Radiology  
Nele.Eley@sonopath.com