

**PATIENT**

Strider Davies

PRESENTING CLINICAL SIGNS

Acutely lame RH leg after playing with other dog
Abnormal PE/Chem/CBC/UA Results: Increased swelling to R stifle, negative drawer but pain on attempt. Lameness has resolved.

SPECIES

Canine

ULTRASONOGRAPHIC FINDINGS**Right Stifle****BREED**

Pointer

A moderate amount of anechoic effusion and moderate synovial swelling are seen in the suprapatellar recess of the right stifle joint. There is a mild amount of effusion in the infrapatellar recess. The infrapatellar fat pad presents uniform with expected echoarchitecture. The patella ligament is thin and smooth.

SEX

Male

The cranial cruciate ligament is continuous and smoothly delineated. No evidence of echoarchitectural changes is seen.

The lateral and medial menisci present in situ and smoothly delineated with uniform internal echoarchitecture.

AGE

10 Months

ULTRASONOGRAPHIC DIAGNOSIS

- Synovialitis and effusion of the right stifle.

INTERPRETED BY

Nele Eley, DVM
Dr. med. Vet. DipECVDI

INTERPRETATION OF THE FINDINGS & FURTHER RECOMMENDATIONS

The ultrasonographic study reveals no evidence of cranial cruciate ligament injury. Presence of edema cannot be ruled out. However, no fiber disruption is seen ultrasonographically. The menisci present within normal limits.

HOSPITAL NAME

Cedarview Animal
Hospital

The effusion and synovialitis are most likely to be traumatic in origin. Inflammatory pathology cannot be ruled out entirely.

REFERRING VET

Nigel Gumley

INVOICE

47994

DATE

10-26-21



PATIENT

Strider Davies

SPECIES

Canine

BREED

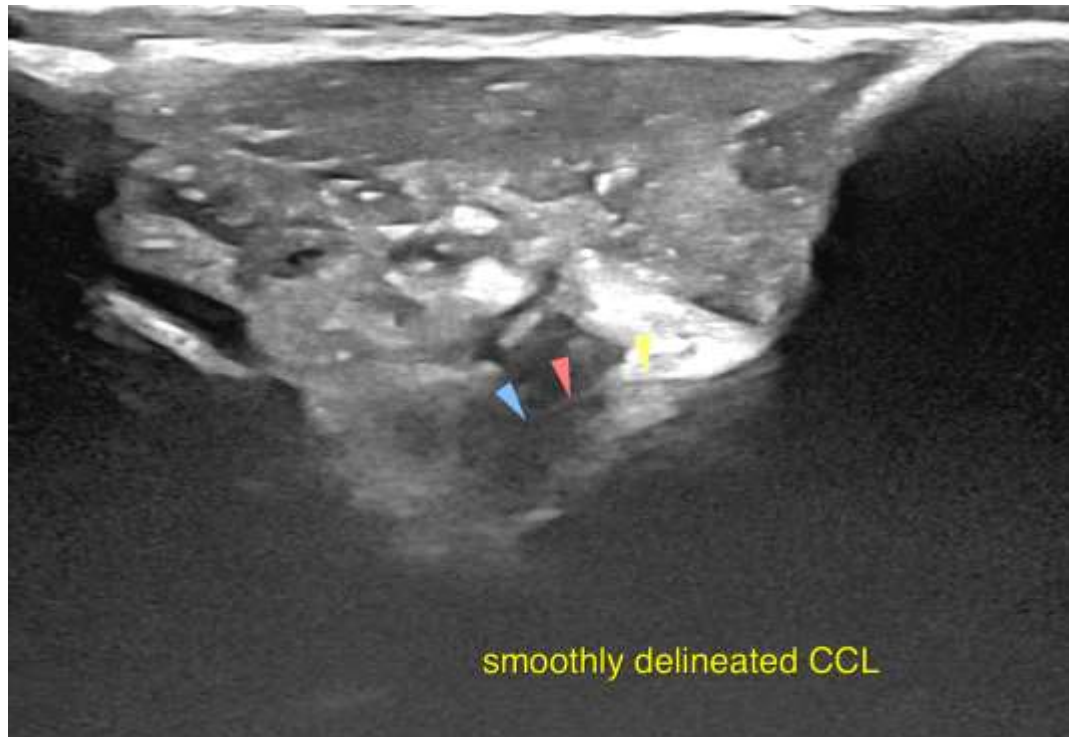
Pointer

SEX

Male

AGE

10 Months



INTERPRETED BY

Nele Eley, DVM
Dr. med. Vet. DipECVDI

The information and recommendations provided are based on the images presented by the referring veterinarian. No evaluation can be communicated regarding pathology that was not visible in the image/video clips provided.

Thank you for this referral. If the clinical or image interpretation does not parallel your findings or if I can be of any further assistance please contact me.

HOSPITAL NAME

Cedarview Animal
Hospital

Nele Eley, DVM, Dr. med. vet., DipECVDI
European Specialist in Veterinary Diagnostic Imaging, Cert. Radiology,
Senior lecturer University of Giessen, Germany, Veterinary Faculty, Department of Radiology
Nele.Eley@sonopath.com

REFERRING VET

Nigel Gumley

INVOICE

47994

DATE

10-26-21