

**PATIENT**

Pebbles Pchakjian

**PRESENTING CLINICAL SIGNS**

Senior pet with severe dental disease, diabetic (control up to this point), O recently lost housemate and is worried about pet's health, doing survey RADS as wellness check. On P.E. Dental Dz, no heart murmur, potbelly, overweight and thinning fur (rat tail appearance)

**SPECIES**

Canine

**RADIOGRAPHIC STUDY OF THE ABDOMEN**

Right lateral and ventrodorsal views totaling 2 images available for review.

**BREED**

Maltese

**RADIOGRAPHIC FINDINGS**

The surrounding bony structures are within normal limits.

A metal clip or suture wire is seen level with the caudal prepuce.

**SEX**

The ventral abdominal wall is pendulous. The abdominal cavity appears to be voluminous.

MN

Both kidneys are seen and present with normal size, shape, delineation and opacity. The urinary bladder is in its anticipated position. No radiopaque calculi are noted throughout the upper and lower urinary tract.

**AGE**

11 Years

Moderate generalized enlargement of the liver with slightly rounded lobar margins is noted. No evidence of abnormal opacities is seen throughout the liver.

**INTERPRETED BY**

Nele Eley, DVM  
Dr. med. Vet. DipECVDI

The stomach is post-prandial.

**RADIOGRAPHIC DIAGNOSIS**

- Hepatomegaly.

**HOSPITAL NAME**

Paws and Claws  
Urgent Care

**INTERPRETATION OF THE FINDINGS & FURTHER RECOMMENDATIONS**

The radiographic study reveals diffuse enlargement of the liver. Consider metabolic/endocrine hepatopathy a potential. Diffuse inflammatory or neoplastic infiltrates cannot be ruled out but are thought less common with the pertinent radiographic findings. Correlate with the laboratory values and consider ultrasound for further definition as indicated.

**REFERRING VET**

Dr. Juarez

**INVOICE**

47996

**DATE**

10-26-21



**PATIENT**

Pebbles Pchakjian

**SPECIES**

Canine

**BREED**

Maltese

**SEX**

MN

**AGE**

11 Years

**INTERPRETED BY**

Nele Eley, DVM  
Dr. med. Vet. DipECVDI

**HOSPITAL NAME**

Paws and Claws  
Urgent Care

**REFERRING VET**

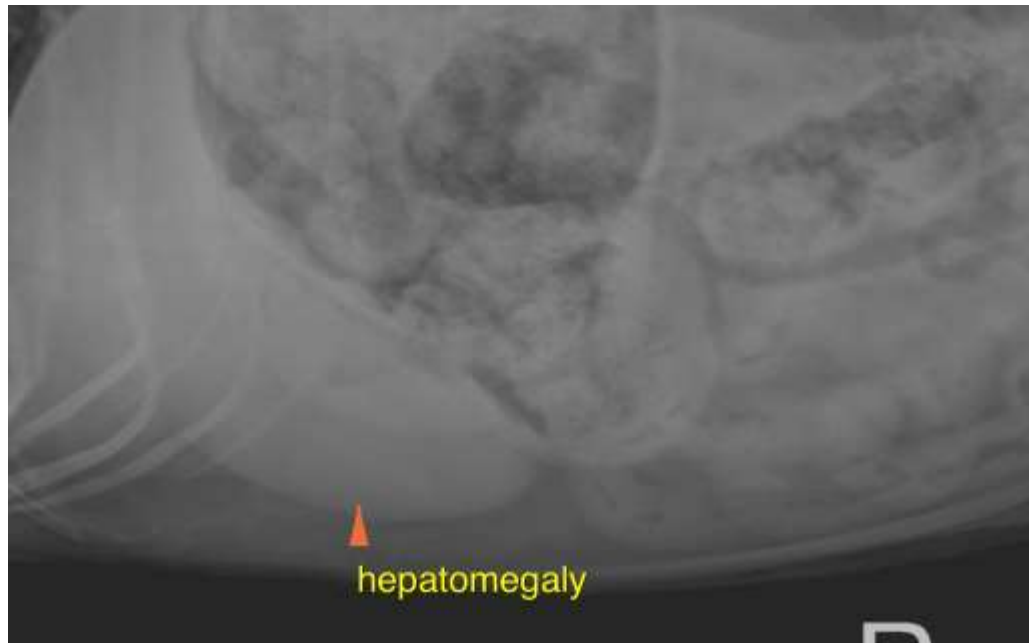
Dr. Juarez

**INVOICE**

47996

**DATE**

10-26-21



The information and recommendations provided are based on the images presented by the referring veterinarian. No evaluation can be communicated regarding pathology that was not visible in the image/video clips provided.

Thank you for this referral. If the clinical or image interpretation does not parallel your findings or if I can be of any further assistance please contact me.

**Nele Eley**, DVM, Dr. med. vet., DipECVDI  
European Specialist in Veterinary Diagnostic Imaging, Cert. Radiology,  
Senior lecturer University of Giessen, Germany, Veterinary Faculty, Department of Radiology  
Nele.Eley@sonopath.com