



PATIENT

Jojo David

PRESENTING CLINICAL SIGNS

Jojo presented for pain of spine week duration. Jojo did respond to medications.

SPECIES

Canine

COMPUTED TOMOGRAPHIC STUDY OF THE THORACOLUMBAR SPINE

CT myelogram of the thoracolumbar spine with lumbar puncture between L6 and L7 available for review.

BREED

Bichon Frise

COMPUTED TOMOGRAPHIC FINDINGS

Displacement of the contrast in the ventral epidural space is seen over the intervertebral disc spaces T12/L13, T13/L1, and L1/2. However, this is at least in part a normal finding with an epidurogram. Otherwise, the number, alignment, and anatomy of the thoracolumbar vertebrae present within normal limits.

SEX

MN

COMPUTED TOMOGRAPHIC DIAGNOSIS

- Open.

AGE

6 Years

INTERPRETATION OF THE FINDINGS & FURTHER RECOMMENDATIONS

The assessment is limited to the availability of an epidurogram which renders it difficult to differentiate between two compressive disc hernia and normal epidural displacement of contrast media level with the intervertebral disc spaces. No overt traumatic osseous injury and no mineral attenuating extrusion is seen. I cannot delineate a single site of compressive myelopathy. If available, feel free to submit the plain and/or IV contrast study for comparison.

INTERPRETED BY

Nele Eley, DVM
Dr. med. Vet. DipECVDI

HOSPITAL NAME

Animal Surgical
Center

REFERRING VET

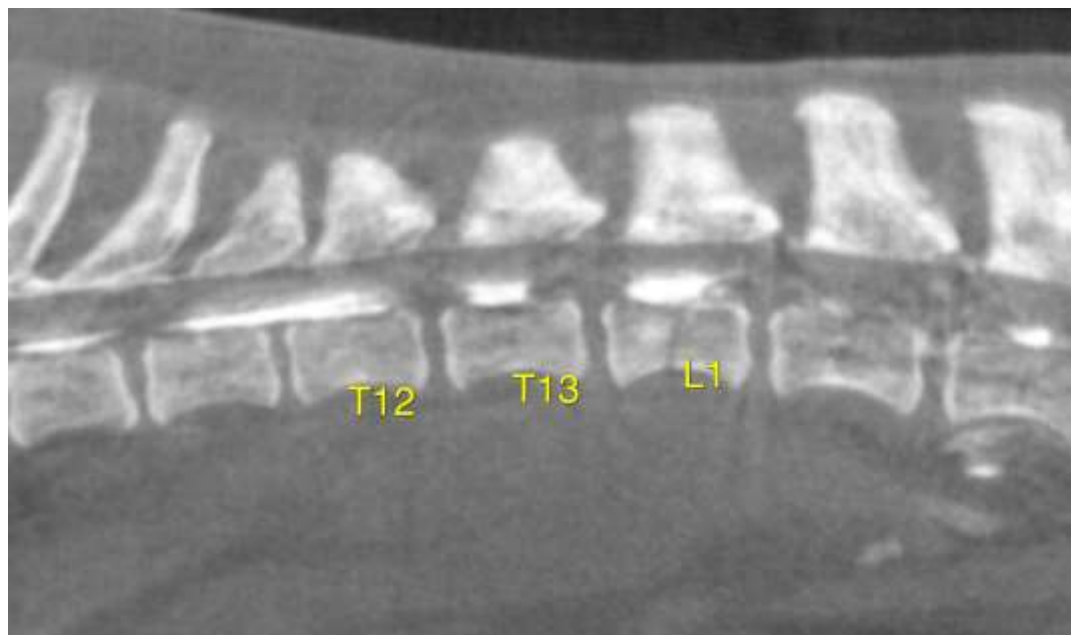
Queens Animal
Health

INVOICE

47997

DATE

10-26-21





PATIENT

Jojo David

The information and recommendations provided are based on the images presented by the referring veterinarian. No evaluation can be communicated regarding pathology that was not visible in the image/video clips provided.

SPECIES

Canine

Thank you for this referral. If the clinical or image interpretation does not parallel your findings or if I can be of any further assistance please contact me.

BREED

Bichon Frise

Nele Eley, DVM, Dr. med. vet., DipECVDI
European Specialist in Veterinary Diagnostic Imaging, Cert. Radiology,
Senior lecturer University of Giessen, Germany, Veterinary Faculty, Department of Radiology
Nele.Eley@sonopath.com

SEX

MN

AGE

6 Years

INTERPRETED BY

Nele Eley, DVM
Dr. med. Vet. DipECVDI

HOSPITAL NAME

Animal Surgical
Center

REFERRING VET

Queens Animal
Health

INVOICE

47997

DATE

10-26-21