



**PATIENT**

Luke Kelly

**PRESENTING CLINICAL SIGNS**

Luke was referred for weight loss, splenic masses diagnosed with US by Dr. Ward. A FNA was performed and diagnosis was hyperplasia. Luke has been also lethargic and having severe decreased appetite. There is some free peritoneal fluid.

**SPECIES**

Canine

**COMPUTED TOMOGRAPHIC STUDY OF THE ABDOMEN & THORAX**

Plain and post contrast studies available for review.

**BREED**

Labrador Retriever

**COMPUTED TOMOGRAPHIC FINDINGS**

**Abdomen**

A 6.5 cm sized hypoattenuating and hypoenhancing mass with cavitations is expanding the splenic tail. The lesion margins to the mesentery are ill-defined. A mild amount of regional peritoneal fluid is seen. The remainder of the spleen presents multiple up to 2.5 cm sized expansile nodules.

**SEX**

MN

Multiple mild mesenteric lymphadenomegaly is noted accentuating the splenic and hepatic lymph nodes in the epigastrium.

**AGE**

7

The liver size, shape, and attenuation are considered within normal limits.

The gallbladder is moderately distended with uniformly fluid attenuating bile.

**INTERPRETED BY**

Nele Eley, DVM  
Dr. med. Vet. DipECVDI

Both kidneys present cortical infarcts. Nephrogram and pyelogram are considered within normal limits.

Both adrenal glands present within normal limits.

**HOSPITAL NAME**

Critical Vet  
Care/Suncoast  
Veterinary

No abnormality of the gastrointestinal tract is seen.

**Thorax**

Moderate atelectasis of the caudodorsal and right lung is seen. No evidence of interstitial pulmonary nodules is noted. There are occasional age related incidental pulmonary osteomas.

**REFERRING VET**

Dr. Young

Mild sternal lymphadenomegaly is present. The cranial mediastinal and tracheobronchial lymph nodes present within normal limits.

There is no evidence of cardiovascular pathology.

**INVOICE**

47916

Course and width of the trachea are considered within normal limits. A 3.5 cm sized intermuscular lipoma is seen in the left pectoralis.

**DATE**

10-22-21



**PATIENT**

Luke Kelly

**SPECIES**

Canine

**BREED**

Labrador Retriever

**SEX**

MN

**AGE**

7

**INTERPRETED BY**

Nele Eley, DVM  
Dr. med. Vet. DipECVDI

**HOSPITAL NAME**

Critical Vet  
Care/Suncoast  
Veterinary

**REFERRING VET**

Dr. Young

**INVOICE**

47916

**DATE**

10-22-21

**COMPUTED TOMOGRAPHIC DIAGNOSIS**

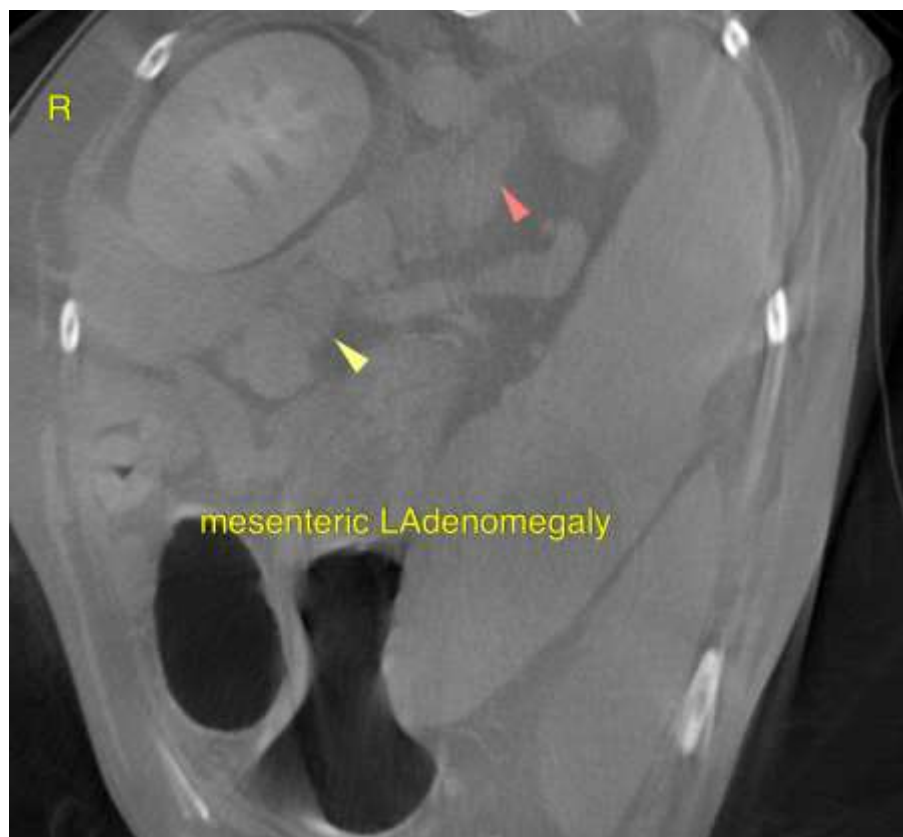- Ruptured splenic mass with regional effusion/hemorrhage.
- Multiple additional splenic nodules.
- Multiple mild mesenteric lymphadenomegaly.
- Cortical renal infarcts - likely to be incidental.
- No evidence of pulmonary metastatic disease.
- Mild sternal lymphadenomegaly.
- Intermuscular lipoma - left pectoralis region.

**INTERPRETATION OF THE FINDINGS & FURTHER RECOMMENDATIONS**

The CT findings are compatible with a ruptured splenic mass. Hematoma, hemangiosarcoma, and hemangioma are the most common and likely differential diagnoses. Nodular hyperplasia is thought unlikely. The multiple splenic nodules may represent nodular hyperplasia, hemangioma, metastatic disease, or other.

There is no evidence of pulmonary metastatic disease.

The regional and sternal lymphadenomegaly is suggestive for reactive hyperplasia. Early metastatic disease cannot be ruled out entirely.





**PATIENT**

Luke Kelly

**SPECIES**

Canine

**BREED**

Labrador Retriever

**SEX**

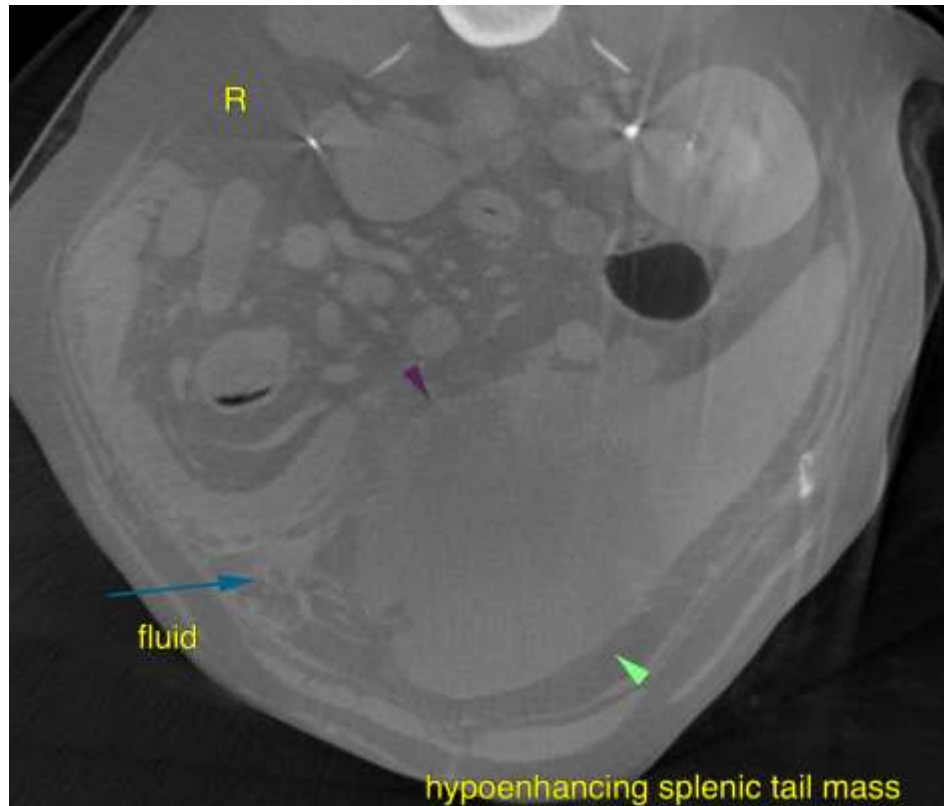
MN

**AGE**

7

**INTERPRETED BY**

Nele Eley, DVM  
Dr. med. Vet. DipECVDI



**HOSPITAL NAME**

Critical Vet  
Care/Suncoast  
Veterinary

**REFERRING VET**

Dr. Young

**INVOICE**

47916

**DATE**

10-22-21

The information and recommendations provided are based on the images presented by the referring veterinarian. No evaluation can be communicated regarding pathology that was not visible in the image/video clips provided.

Thank you for this referral. If the clinical or image interpretation does not parallel your findings or if I can be of any further assistance please contact me.

**Nele Eley, DVM, Dr. med. vet., DipECVDI**  
European Specialist in Veterinary Diagnostic Imaging, Cert. Radiology,  
Senior lecturer University of Giessen, Germany, Veterinary Faculty, Department of Radiology  
Nele.Eley@sonopath.com