



PATIENT

Lily Blando

PRESENTING CLINICAL SIGNS

Patient presents for a COHAT. A survey CT of her skull is submitted for review with emphasis on the dental arcade.

Abnormal PE/Chem/CBC/UA Results: Pre-op lab work - NSF

SPECIES

Canine

COMPUTED TOMOGRAPHIC STUDY OF THE DENTAL ARCADES

Plain study available for review.

BREED

Chihuahua

COMPUTED TOMOGRAPHIC FINDINGS

The dentition is incomplete. Triadans 206, 308, 406, and 408 are absent. A root remnant of the Triadan 105 is seen.

SEX

FS

Multifocal periodontal space widening is seen and most pronounced and moderate in degree affecting the Triadans 107, 108, 204, 205, 209, 210, 401, 402, and 403.

No evidence of a dental nasal fistula is seen.

AGE

8 Years, 4 Months

Moderate horizontal atrophy of the alveolar crest is seen in all quadrants accentuating the incisor portions.

The position of the teeth is narrow with overlap in tooth roots as typical in brachycephalic dogs.

INTERPRETED BY

Nele Eley, DVM
Dr. med. Vet. DipECVDI

COMPUTED TOMOGRAPHIC DIAGNOSIS

- Multifocal moderate to severe periodontal disease of the Triadans 107, 108, 204, 205, 209, 210, 401, 402, and 403.
- Moderate generalized alveolar crest atrophy.

HOSPITAL NAME

South Bay Animal
Hospital

INTERPRETATION OF THE FINDINGS & FURTHER RECOMMENDATIONS

Clinical correlation is required in order to determine the need for extractions of the teeth that are most severely effected by widening of their periodontium. The CT findings should be referenced specifically to the clinical workup of the Triadans 108, 204, 205, 209, 210, 401, 402, and 403.

REFERRING VET

Ravinder Atwal, DVM,
CCRP

INVOICE

47919

DATE

10-22-21



PATIENT

Lily Blando

SPECIES

Canine

BREED

Chihuahua

SEX

FS

AGE

8 Years, 4 Months

INTERPRETED BY

Nele Eley, DVM
Dr. med. Vet. DipECVDI

HOSPITAL NAME

South Bay Animal
Hospital

REFERRING VET

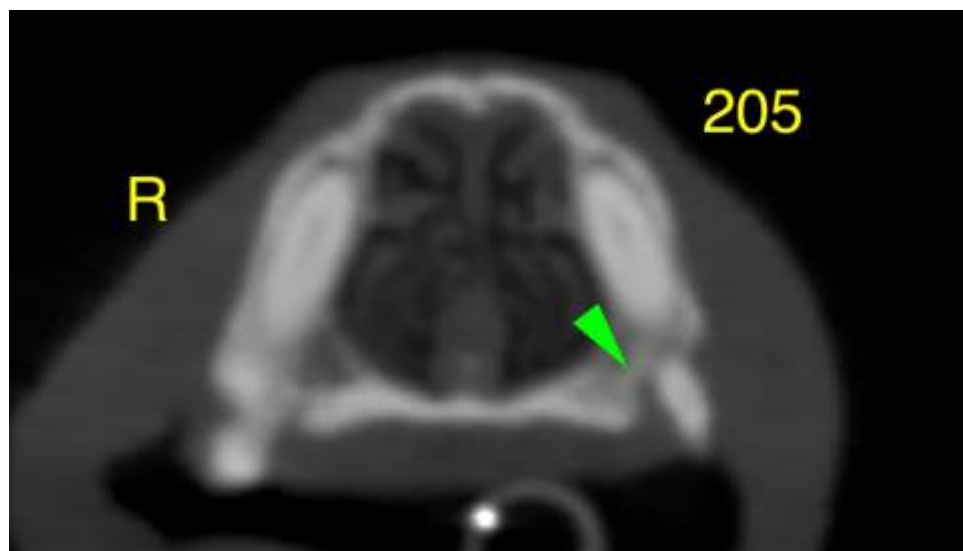
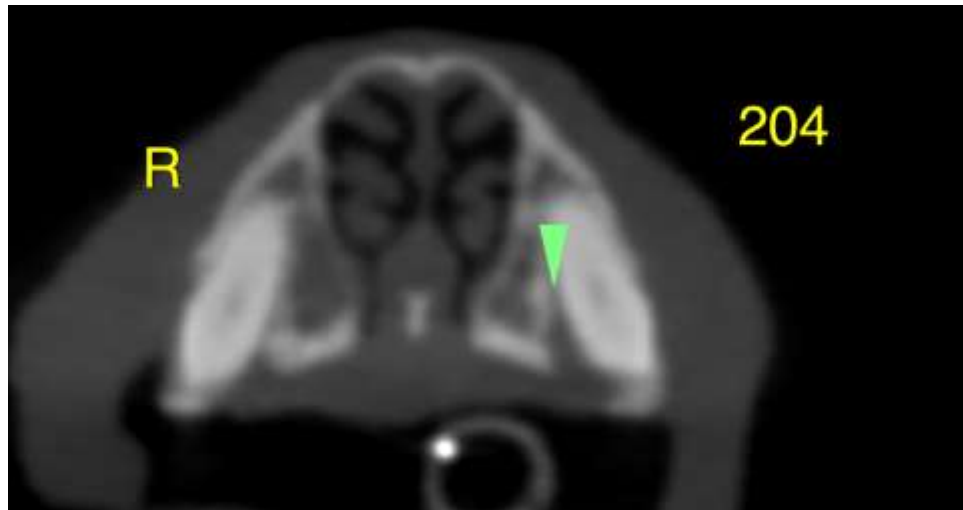
Ravinder Atwal, DVM,
CCRP

INVOICE

47919

DATE

10-22-21





PATIENT

Lily Blando

SPECIES

Canine

BREED

Chihuahua

SEX

FS

AGE

8 Years, 4 Months

INTERPRETED BY

Nele Eley, DVM
Dr. med. Vet. DipECVDI

HOSPITAL NAME

South Bay Animal
Hospital

REFERRING VET

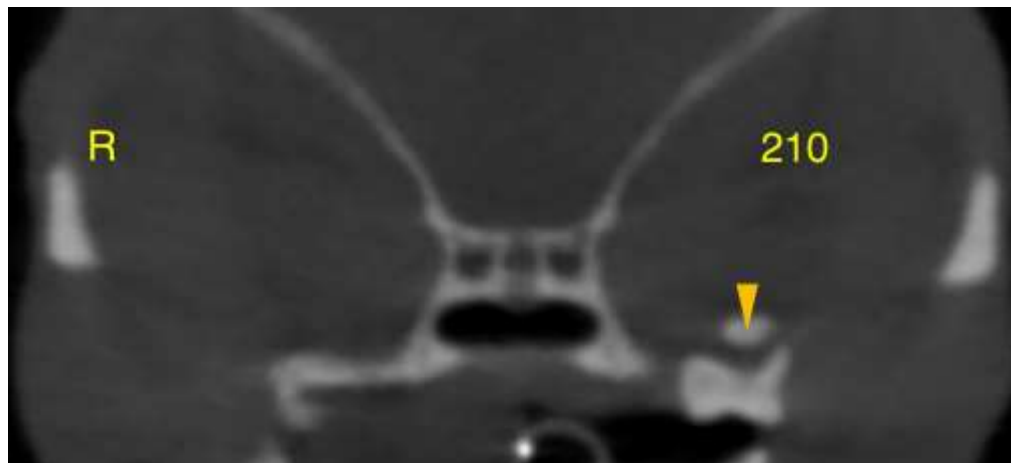
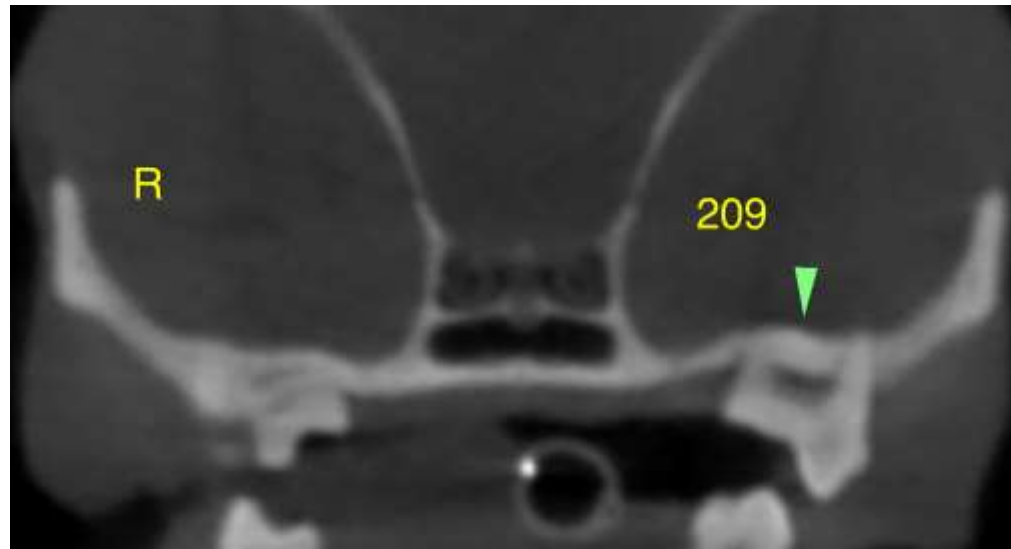
Ravinder Atwal, DVM,
CCRP

INVOICE

47919

DATE

10-22-21



The information and recommendations provided are based on the images presented by the referring veterinarian. No evaluation can be communicated regarding pathology that was not visible in the image/video clips provided.

Thank you for this referral. If the clinical or image interpretation does not parallel your findings or if I can be of any further assistance please contact me.

Nele Eley, DVM, Dr. med. vet., DipECVDI
European Specialist in Veterinary Diagnostic Imaging, Cert. Radiology,
Senior lecturer University of Giessen, Germany, Veterinary Faculty, Department of Radiology
Nele.Eley@sonopath.com