

**PATIENT**

Guinness Harris

SPECIES

Canine

BREED

Australian Shepherd

SEX

MA

AGE

1 Year

INTERPRETED BYNele Eley, DVM
Dr. med. Vet. DipECVDI**HOSPITAL NAME**Boca Park Animal
Hospital**REFERRING VET**

Dr. Corinna Gorgon

INVOICE

47929

DATE

10-22-21

PRESENTING CLINICAL SIGNS

Patient presented for lethargy, low energy and vomiting once last week. Owner states is normally high energy and doesn't have problems like this. Got into a toy and vomited that last week, was at the dog park yesterday. Owner unsure if ate anything last night but did not eat dinner and did not eat breakfast this morning.

Abnormal PE/Chem/CBC/UA Results: Ataxic on exam, falls to the right, slow PLRs, hyperreactive to menace (possible marijuana toxicity?)

RADIOGRAPHIC STUDY OF THE ABDOMEN

Right/left lateral and ventrodorsal views of the abdomen and single lateral view of the thorax totaling 4 images available for review.

Abdominal read requested.

RADIOGRAPHIC FINDINGS

The stomach contains several soft tissue opaque structures; some of which are relatively square in shape. A mild amount of gas is present within the stomach as well.

Mild dilation of the descending duodenum, which is highlighted by gas on the left lateral view, is present. However, the remainder of the small intestinal loops are evenly distributed throughout the mid abdomen without evidence of abnormal dilation, plication, or radiopaque foreign material.

RADIOGRAPHIC DIAGNOSIS

- Suspect gastric foreign material.
- Functional duodenal ileus.

INTERPRETATION OF THE FINDINGS & FURTHER RECOMMENDATIONS

Depending on the feeding history of the patient, the presence of small pieces of soft tissue opaque foreign material within the stomach should be considered. Further verification could be performed by recheck radiographs with the patient being NPO for 6 hours eventually followed by positive contrast swallow or using ultrasound. At this point, there is no radiographic evidence of mechanical small intestinal ileus.



PATIENT

Guinness Harris

SPECIES

Canine

BREED

Australian Shepherd

SEX

MA

AGE

1 Year

INTERPRETED BY

Nele Eley, DVM
Dr. med. Vet. DipECVDI

HOSPITAL NAME

Boca Park Animal
Hospital

REFERRING VET

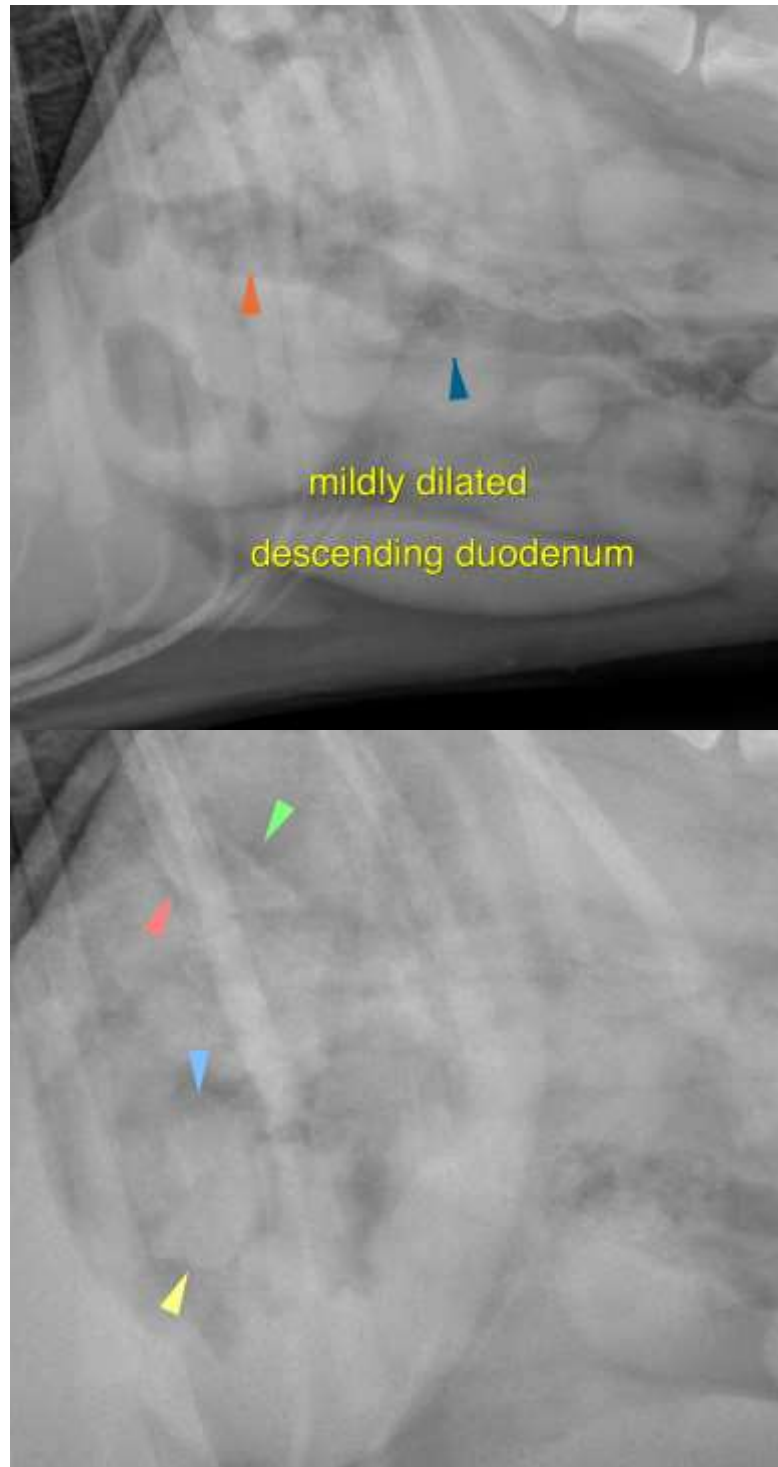
Dr. Corinna Gorgon

INVOICE

47929

DATE

10-22-21





PATIENT

Guinness Harris

The information and recommendations provided are based on the images presented by the referring veterinarian. No evaluation can be communicated regarding pathology that was not visible in the image/video clips provided.

SPECIES

Canine

Thank you for this referral. If the clinical or image interpretation does not parallel your findings or if I can be of any further assistance please contact me.

BREED

Australian Shepherd

Nele Eley, DVM, Dr. med. vet., DipECVDI
European Specialist in Veterinary Diagnostic Imaging, Cert. Radiology,
Senior lecturer University of Giessen, Germany, Veterinary Faculty, Department of Radiology
Nele.Eley@sonopath.com

SEX

MA

AGE

1 Year

INTERPRETED BY

Nele Eley, DVM
Dr. med. Vet. DipECVDI

HOSPITAL NAME

Boca Park Animal
Hospital

REFERRING VET

Dr. Corinna Gorgon

INVOICE

47929

DATE

10-22-21