



**PATIENT PRESENTING CLINICAL SIGNS**

Rascal Murphy Was found as a stray Aug 2021. Has been coughing several times a day (throughout day and night). Cough started as a hack but has recently progressed to wet. Last night owner noticed increased effort on exhalation. PU/PD

**SPECIES** Abnormal PE/Chem/CBC/UA Results: Bloodwork and UA pending 4/4 periodontal disease grade 2/6 systolic murmur sensitive trachea BCS 4/9, Sarcopenic

Canine

**RADIOGRAPHIC STUDY OF THE THORAX**

**BREED** Right/left lateral and dorsoventral whole body views totaling 6 images available for review.

Chihuahua Thoracic read requested.

**RADIOGRAPHIC FINDINGS**

**SEX** The patient is thin.

MN Spondyloses are seen between T13/L1 and L1/2. Bilateral shoulder osteoarthritis is noted.

**AGE** The degree of pulmonary inflation is moderate. The chest is expanded with relatively far cranial excursion of the diaphragm. The intrathoracic trachea and main lobar bronchi are wide indicating deep inhalation.

10 Years

A mild generalized bronchointerstitial pattern is seen and considered within age related normal limits.

**INTERPRETED BY**

Nele Eley, DVM  
Dr. med. Vet. DipECVDI

Moderate cervical tracheal collapse is noted on one of the lateral views.

The cardiac silhouette is relatively square in shape and mild loss of the caudal cardiac waist may be present; however, vertebral heart score is 9.5 and no overall enlargement of the cardiac silhouette is seen. There is no evidence of pulmonary venous dilation or cardiogenic pulmonary edema.

**HOSPITAL NAME**

Companion Animal  
Clinic

There is progressive gastric aerophagia. Esophageal aerophagia is noted as well.

**REFERRING VET**

Varinia Acosta

**RADIOGRAPHIC DIAGNOSIS**

- Moderate dynamic cervical tracheal collapse with upper airway obstruction.
- Normal age related lung.
- Potential for early left atrial enlargement without evidence of congestive heart failure or generalized cardiomegaly.
- Aerophagia which may be contributed to by excitement and respiratory distress.

**INVOICE**

47910

**INTERPRETATION OF THE FINDINGS & FURTHER RECOMMENDATIONS**

**DATE**

10-21-21

The main finding appears to be the presence of moderate dynamic cervical tracheal collapse. No evidence of structural lung pathology is seen. Early left atrial enlargement cannot be ruled out; however, there appear to be no hemodynamic consequences at this point. A detailed assessment would require a cardiac echo.



**PATIENT**

Rascal Murphy

**SPECIES**

Canine

**BREED**

Chihuahua

**SEX**

MN

**AGE**

10 Years

**INTERPRETED BY**

Nele Eley, DVM  
Dr. med. Vet. DipECVDI

**HOSPITAL NAME**

Companion Animal  
Clinic

**REFERRING VET**

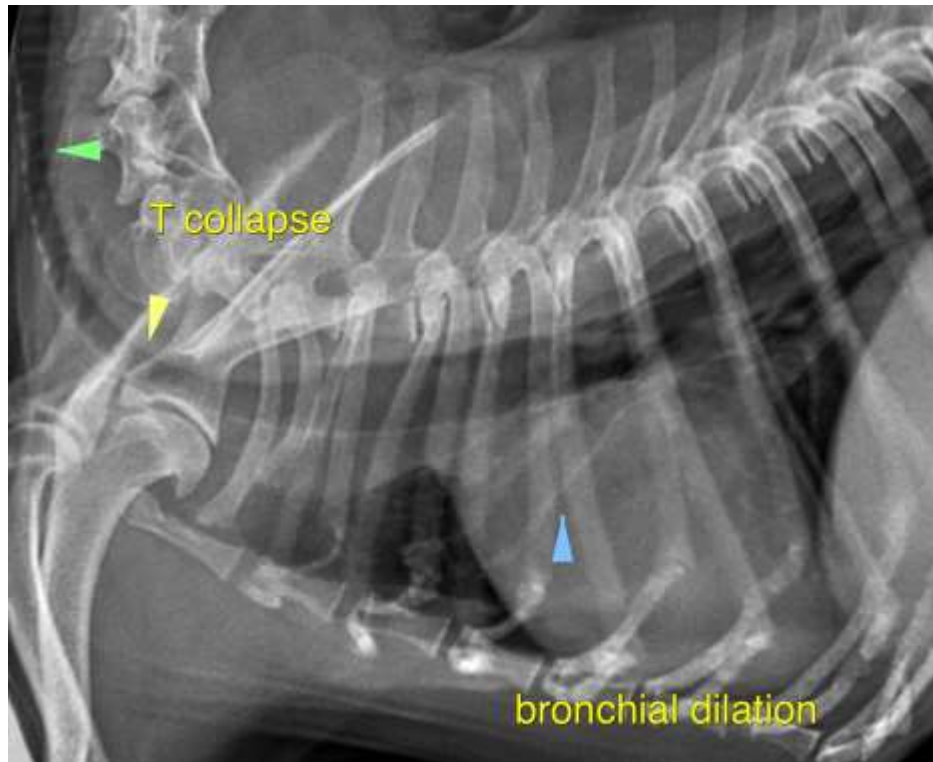
Varinia Acosta

**INVOICE**

47910

**DATE**

10-21-21



The information and recommendations provided are based on the images presented by the referring veterinarian. No evaluation can be communicated regarding pathology that was not visible in the image/video clips provided.

Thank you for this referral. If the clinical or image interpretation does not parallel your findings or if I can be of any further assistance please contact me.

**Nele Eley, DVM, Dr. med. vet., DipECVDI**  
European Specialist in Veterinary Diagnostic Imaging, Cert. Radiology,  
Senior lecturer University of Giessen, Germany, Veterinary Faculty, Department of Radiology  
Nele.Eley@sonopath.com