



PATIENT

Basho Lall

PRESENTING CLINICAL SIGNS

As per Owner, no clinical signs yet - no fainting/syncope or exercise intolerance, random coughing.
Abnormal PE/Chem/CBC/UA Results: Grade 3-4 heart murmur.

SPECIES

Canine

RADIOGRAPHIC STUDY OF THE THORAX

Right/left lateral and ventrodorsal views of the thorax totaling 3 images available for review.

BREED

Miniature Schnauzer

RADIOGRAPHIC FINDINGS

The degree of pulmonary inflation is deep.

The lung and bronchial tree present within age related normal limits. Multiple incidental and age related pulmonary osteomas are seen.

SEX

Spayed Female

There is mild redundancy of the dorsal tracheal ligament of the caudal cervical trachea.

AGE

10 Years

Mild left atrial tenting is noted with a vertebral heart score of 10.9 with reference range up to 10.5. No evidence of a vascular lung pattern or congestive heart failure is noted.

Mild gastric aerophagia is noted.

INTERPRETED BY

Nele Eley, DVM
Dr. med. Vet. DipECVDI

RADIOGRAPHIC DIAGNOSIS

- Mild left sided cardiomegaly with no evidence of cardiogenic pulmonary edema/congestive heart failure.
- Normal age related lung.
- Redundant dorsal tracheal ligament.

HOSPITAL NAME

Truscott Animal Hospital

INTERPRETATION OF THE FINDINGS & FURTHER RECOMMENDATIONS

The radiographic presentation of the lung and bronchial tree is considered within normal limits.

Mild left sided cardiomegaly with mild left atrial enlargement is noted. There may be a mild mass effect of the left atrium onto the left mainstem bronchus contributing to the occasional coughing.

REFERRING VET

Dr. Medhat Meawad

Redundancy of the dorsal tracheal ligament is typically an incidental finding however it can be associated with dynamic tracheal disease. Clinical correlation is required.

INVOICE

54751

A full cardia echo could be considered for further definition and staging of the cardiac disease.

DATE

10-20-22



PATIENT

Basho Lall

SPECIES

Canine

BREED

Miniature Schnauzer

SEX

Spayed Female

AGE

10 Years

INTERPRETED BY

Nele Eley, DVM
Dr. med. Vet. DipECVDI

HOSPITAL NAME

Truscott Animal
Hospital

REFERRING VET

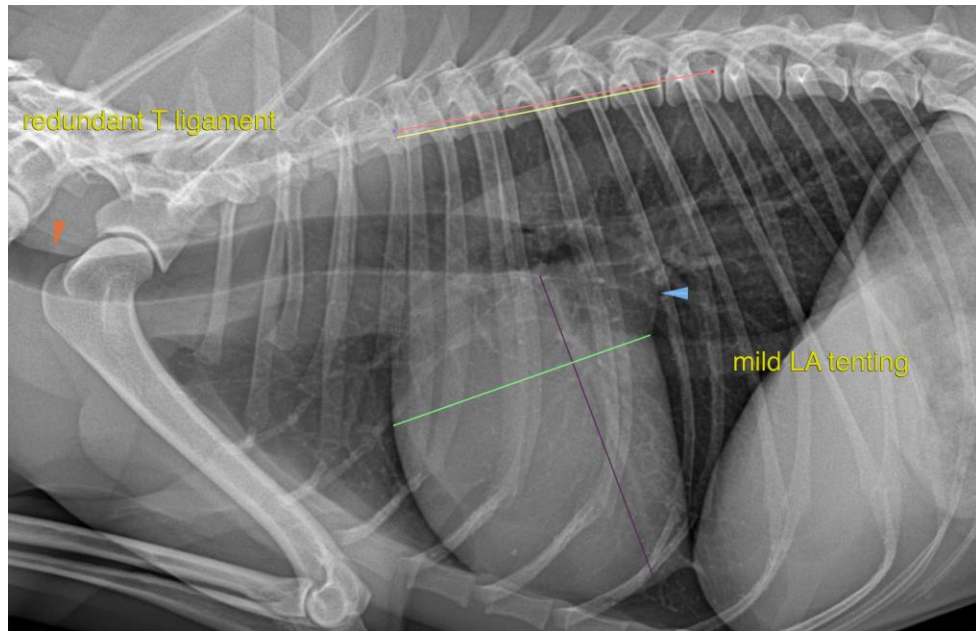
Dr. Medhat Meawad

INVOICE

54751

DATE

10-20-22



The information and recommendations provided are based on the images presented by the referring veterinarian/sonographer. No evaluation can be communicated regarding pathology that was not visible in the image/video clips provided.

Thank you for this referral. If the clinical or image interpretation does not parallel your findings or if I can be of any further assistance please contact me.

Nele Eley, DVM, Dr. med. vet., DipECVDI
European Specialist in Veterinary Diagnostic Imaging, Cert. Radiology,
Senior lecturer University of Giessen, Germany, Veterinary Faculty, Department of Radiology
Nele.Eley@sonopath.com