



**PATIENT**

Rica Wolfrom

**PRESENTING CLINICAL SIGNS**

sneezing episodes with bilateral epistaxis. great response to Chlorpheniramine, Cerenia, and Clavamox. When medications finished, epistaxis returned.

**SPECIES**

K9

**COMPUTED TOMOGRAPHIC STUDY OF THE HEAD**

Plain and post contrast studies available for review.

**BREED**

Boykin Mix

**COMPUTED TOMOGRAPHIC FINDINGS**

The brain presents no deviation from normal anatomy and symmetry. The grey and white matter distinction and the neuroparenchymal attenuation are as expected. The distribution of contrast enhancement is within normal limits throughout the parenchyma and meninges. The ventricular system is non-dilated and within the limits of the expected volume and symmetry.

**SEX**

FS

An approximately 3.5 x 2.5 cm sized irregular shaped soft tissue attenuating mass is seen within the caudal half of the right nasal cavity. Moderate nonuniform contrast enhancement is seen. There is extensive turbinate destruction and polyostotic aggressive osteolysis involving the right nasal, maxillary, and palatinal bones as well as the right bony orbita and cribriform plate allowing for extension into the right orbita and cranial vault. Partial obstruction of the nasal fundus is seen.

**AGE**

9 Years

A mild amount of fluid attenuating material with a meniscus sign is seen within the right frontal sinus.

**INTERPRETED BY**

Nele Eley, DVM  
Dr. med. Vet. DipECVDI

Both temporomandibular joints present congruent joint spaces with even subchondral bone surfaces and are considered within normal limits.

Both tympanic bullae are aerated, the mucosal lining is not seen, the bony wall is smooth and thin. The external auditory meatuses present within normal limits.

**HOSPITAL NAME**

Animal Medical  
Center of Mt.  
Pleasant

The submandibular and medial retropharyngeal lymph nodes are small and elongated with a normal short-to-long-axis-ratio is < 0.5, the attenuation and contrast enhancement pattern is uniform.

The salivary glands present within normal limits.

**REFERRING VET**

Dr. Steven Epstein

The visible dentition is within normal limits.

**COMPUTED TOMOGRAPHIC DIAGNOSIS**

- Soft tissue mass with aggressive biological behavior and intracranial as well as right orbital extension within the right nasal cavity.
- Obstructive right sided frontal sinusitis.
- No evidence of metastatic disease to the regional lymph nodes.

**INVOICE**

47873

**INTERPRETATION OF THE FINDINGS & FURTHER RECOMMENDATIONS**

**DATE**

10-20-21

The CT findings are consistent with malignant neoplasia of the right nasal cavity with polyostotic aggressive osteolysis and intracranial as well as right orbital extension. Partial upper airway obstruction and obstructive right frontal sinusitis are noted. Differential diagnosis includes nasal



**PATIENT**

Rica Wolfrom

adenocarcinoma, other carcinoma, and lymphosarcoma. Other neoplasia cannot be ruled out entirely but is less common and less likely. Final diagnosis would require sampling for histology. Note the intracranial extension with early extra-axial mass effect and extended into the right orbita.

**SPECIES**

K9

**BREED**

Boykin Mix

**SEX**

FS

**AGE**

9 Years

**INTERPRETED BY**

Nele Eley, DVM  
Dr. med. Vet. DipECVDI

**HOSPITAL NAME**

Animal Medical  
Center of Mt.  
Pleasant

**REFERRING VET**

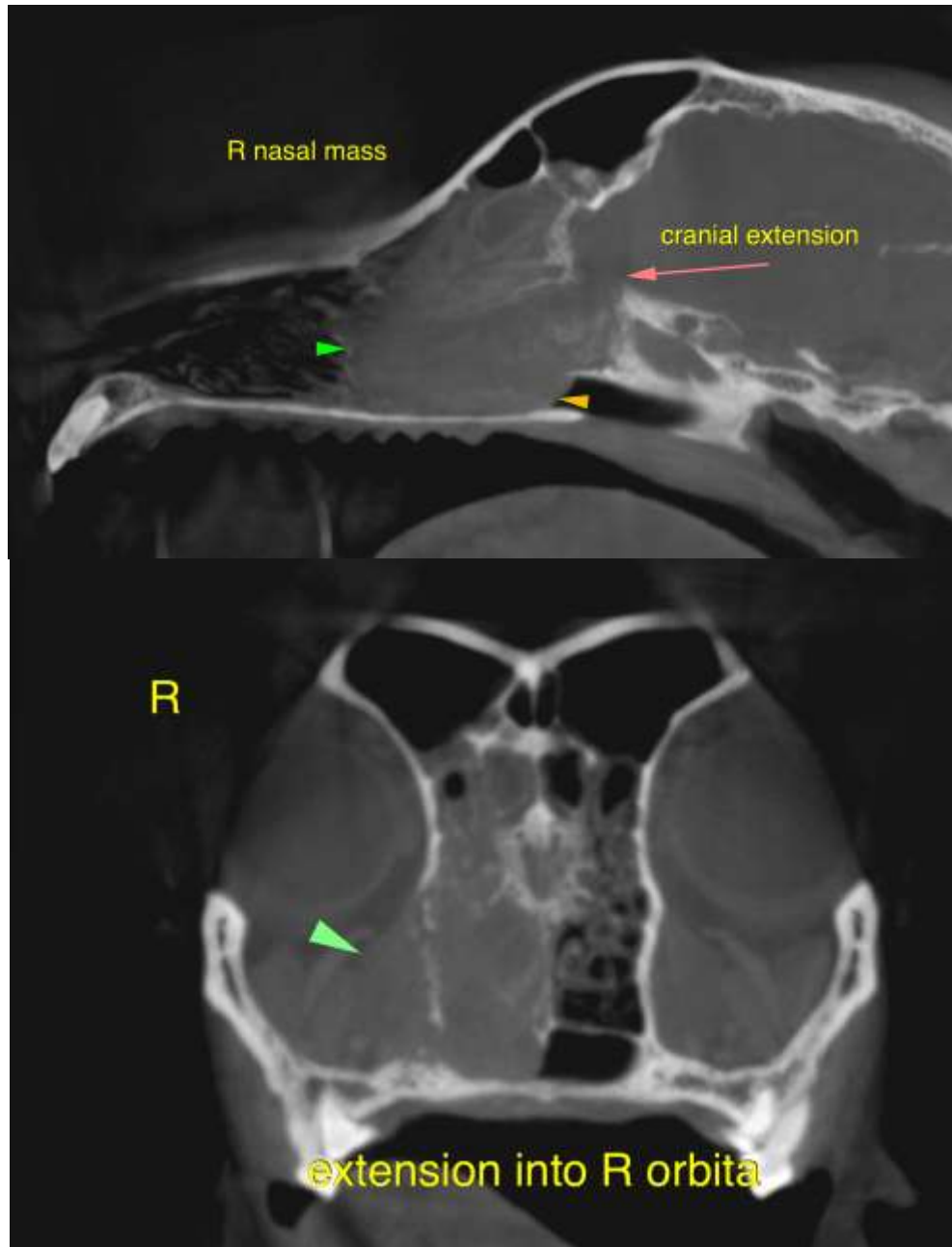
Dr. Steven Epstein

**INVOICE**

47873

**DATE**

10-20-21





**PATIENT**

Rica Wolfrom

The information and recommendations provided are based on the images presented by the referring veterinarian. No evaluation can be communicated regarding pathology that was not visible in the image/video clips provided.

Thank you for this referral. If the clinical or image interpretation does not parallel your findings or if I can be of any further assistance please contact me.

**SPECIES**

K9

**Nele Eley**, DVM, Dr. med. vet., DipECVDI  
European Specialist in Veterinary Diagnostic Imaging, Cert. Radiology,  
Senior lecturer University of Giessen, Germany, Veterinary Faculty, Department of Radiology  
Nele.Eley@sonopath.com

**BREED**

Boykin Mix

**SEX**

FS

**AGE**

9 Years

**INTERPRETED BY**

Nele Eley, DVM  
Dr. med. Vet. DipECVDI

**HOSPITAL NAME**

Animal Medical  
Center of Mt.  
Pleasant

**REFERRING VET**

Dr. Steven Epstein

**INVOICE**

47873

**DATE**

10-20-21