

**PATIENT**

Lily Hipkiss

**PRESENTING CLINICAL SIGNS**

Attached are two sets of abdominal radiographs for review , on pre-surgical showing bladder stones , the second set is post surgery . pleas confirm whether there are stones left or not , if there are stones , are they extra or intra bladder thank you

**SPECIES**

Canine

**RADIOGRAPHIC STUDY OF THE ABDOMEN**

2 right/left lateral views of the caudal abdomen prior to cystotomy and 2 lateral views post-cystotomy available for review.

**BREED**

St Bernard

**RADIOGRAPHIC FINDINGS**

Severe distension of the urinary bladder and presence of multiple well delineated radiopaque urinary bladder calculi are noted on the pre-surgical radiographs.

**SEX**

Female Spayed

There is moderate pneumoperitoneum thickening and ill defined fascial planes as well as metal clips in the caudoventral midline on the post-surgical radiographs.

**AGE**

5 Years

The urinary bladder is moderately distended and contains fluid as well as gas. Moreover, three polygonal shaped well delineated opacities compatible with residual urinary bladder calculi of 5mm, 6mm, and 7mm diameter are seen cranially within the urinary bladder. Two polygonal shaped opacities of 6mm and 5mm diameter are seen level with the urinary bladder neck.

**INTERPRETED BY**

Nele Eley, DVM  
Dr. med. Vet. DipECVDI

**RADIOGRAPHIC DIAGNOSIS**

- Suspect presence of 5 residual urinary bladder calculi.

**INTERPRETATION OF THE FINDINGS & FURTHER RECOMMENDATIONS****HOSPITAL NAME**

St. Catharine's Animal  
Hospital

The post-surgical radiographs suggest presence of 5 urinary bladder calculi which appear to be contained within the urinary bladder, 3 of which are situated within the cranial and 2 more are seen level with the caudal aspect of the urinary bladder neck. Based on the radiographic findings, they all appear to be contained within the urinary bladder / bladder neck. The pelvic urethra is not fully included.

**REFERRING VET**

Dr. Boctor

**INVOICE**

47874

**DATE**

10-20-21



**PATIENT**

Lily Hipkiss

**SPECIES**

Canine

**BREED**

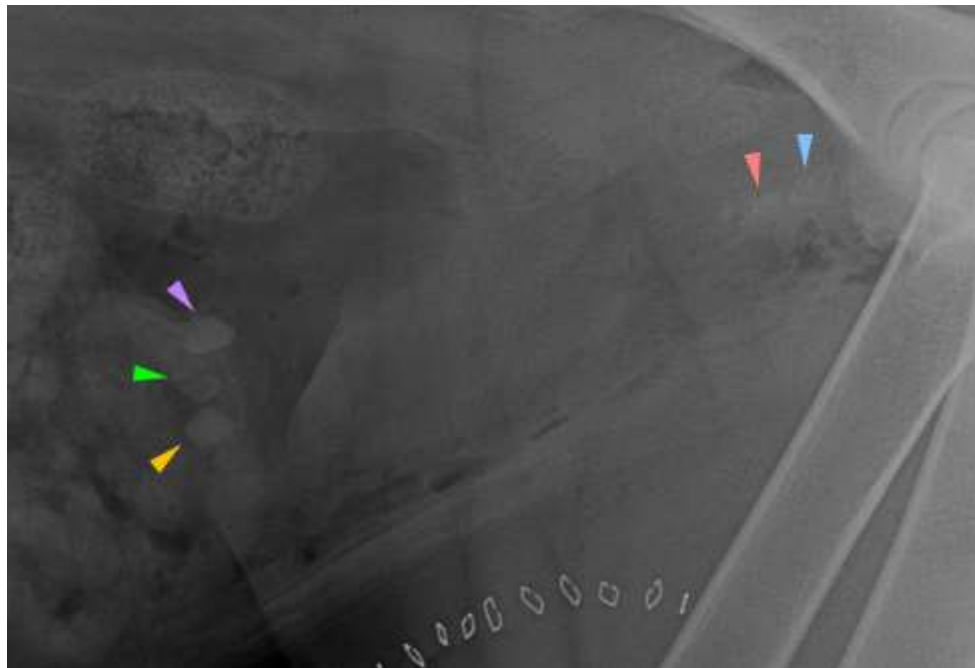
St Bernard

**SEX**

Female Spayed

**AGE**

5 Years



**INTERPRETED BY**

Nele Eley, DVM  
Dr. med. Vet. DipECVDI

The information and recommendations provided are based on the images presented by the referring veterinarian. No evaluation can be communicated regarding pathology that was not visible in the image/video clips provided.

Thank you for this referral. If the clinical or image interpretation does not parallel your findings or if I can be of any further assistance please contact me.

**HOSPITAL NAME**

St. Catharine's Animal  
Hospital

**Nele Eley**, DVM, Dr. med. vet., DipECVDI  
European Specialist in Veterinary Diagnostic Imaging, Cert. Radiology,  
Senior lecturer University of Giessen, Germany, Veterinary Faculty, Department of Radiology  
Nele.Eley@sonopath.com

**REFERRING VET**

Dr. Boctor

**INVOICE**

47874

**DATE**

10-20-21