



PATIENT PRESENTING CLINICAL SIGNS

Willie Ziller presented for re-occurring left sided ear infections. suspected right sided polyp
Abnormal PE/Chem/CBC/UA Results: normal

SPECIES COMPUTED TOMOGRAPHIC STUDY OF THE HEAD & THORAX

Feline Plain and post contrast studies of the head and post contrast study of the thorax available for review.

BREED COMPUTED TOMOGRAPHIC FINDINGS

DSH **Head**

SEX

MN The left tympanic bulla is filled with fluid attenuating contrast negative material. Swelling and increased enhancement of the mucosal lining of the tympanic bulla are seen. There is thickening of the osseous wall of the left tympanic bulla. Significant bone erosion of the petrous temporal bone and inner ear labyrinthium as well as inner ear cochlea are noted with regional intracranial enhancement level with the cranial nerves 7 and 8.

AGE

3 A well delineated elongated soft tissue mass of approximately 2.0 cm length and 6mm diameter is occupying and expanding the lumen of the left external auditory meatus. The remainder of the meatus contains a moderate amount of fluid attenuating contrast negative material.

INTERPRETED BY

Nele Eley, DVM
Dr. med. Vet. DipECVDI

A small stalk like soft tissue mass of 7 x 4mm is seen within the left dorsal nasopharynx with connection to the widened auditive tube.

The left medial retropharyngeal lymph node presents mild symmetric enlargement.

Thorax

HOSPITAL NAME

Northeast Veterinary
Referral Hospital

The bony and surrounding soft tissue structures are within normal limits.

The sternal, cranial mediastinal and tracheobronchial lymph nodes are small elongated with a normal short-to-long-axis-ratio is < 0.5, the attenuation and contrast enhancement pattern are uniform and considered within normal limits.

REFERRING VET

Dr. Runde

The cardiovascular structures including the pulmonary vasculature are within normal limits.

The bronchial tree presents with regular branching and tapers uniformly towards the periphery as expected, the bronchial walls are thin and smooth. The bronchus-to-artery ratio is within normal limits.

INVOICE

54714

The lung parenchyma presents the expected architecture and attenuation behavior.

Small incidental gas pockets are seen within the esophageal lumen, there is no evidence of abnormal dilation.

DATE

10-19-22



PATIENT

Willie Ziller

SPECIES

Feline

BREED

DSH

SEX

MN

AGE

3

INTERPRETED BY

Nele Eley, DVM
Dr. med. Vet. DipECVDI

HOSPITAL NAME

Northeast Veterinary
Referral Hospital

REFERRING VET

Dr. Runde

INVOICE

54714

DATE

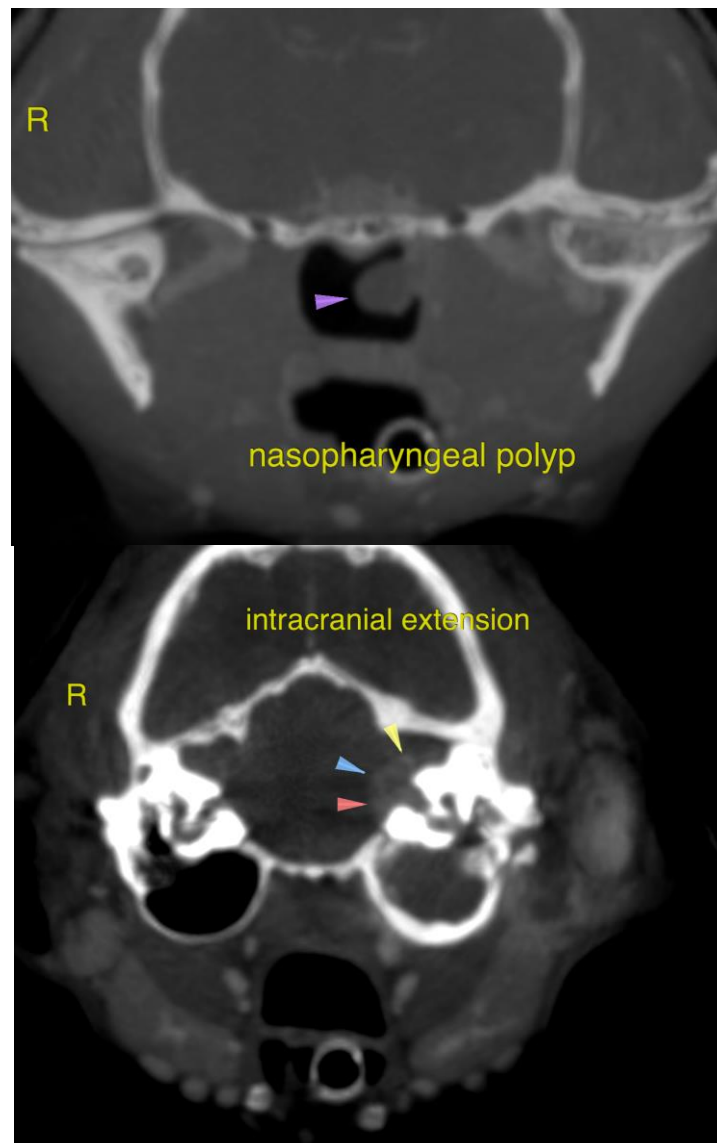
10-19-22

COMPUTED TOMOGRAPHIC DIAGNOSIS

- Severe chronic left sided otitis media and interna with intracranial extension and ear canal as well as nasopharyngeal polyp formation.
- Mild left sided medial retropharyngeal lymphadenitis.

INTERPRETATION OF THE FINDINGS & FURTHER RECOMMENDATIONS

The CT findings are compatible with chronic inflammatory polyps within the left external auditory meatus and left nasopharynx as a consequence of long standing severe otitis media with extension to the inner ear and cranial vault. Involvement of the regional meninges as well as of the cranial nerves 7 and 8 on the left side is considered likely based on the distribution of the CT changes.





PATIENT

Willie Ziller

SPECIES

Feline

BREED

DSH

SEX

MN

AGE

3

INTERPRETED BY

Nele Eley, DVM
Dr. med. Vet. DipECVDI

HOSPITAL NAME

Northeast Veterinary
Referral Hospital

REFERRING VET

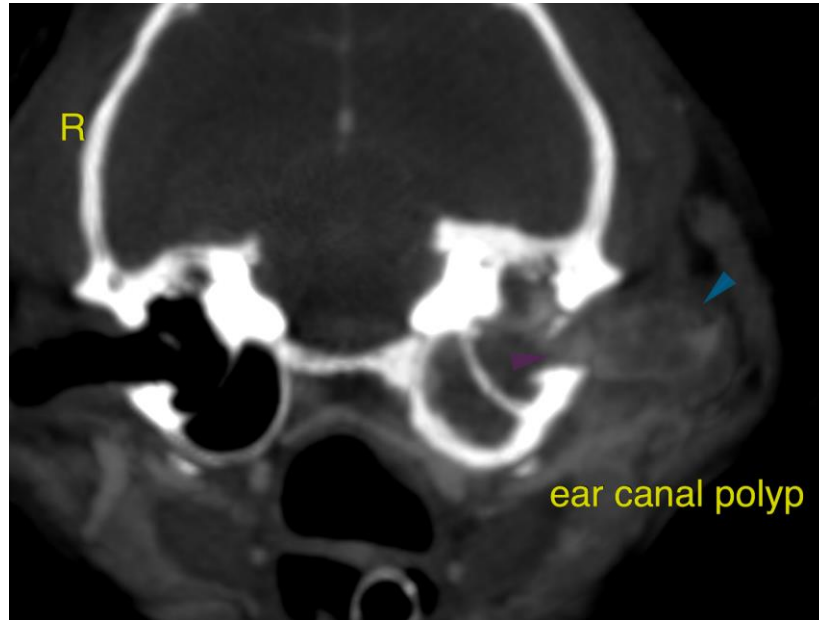
Dr. Runde

INVOICE

54714

DATE

10-19-22



The information and recommendations provided are based on the images presented by the referring veterinarian/sonographer. No evaluation can be communicated regarding pathology that was not visible in the image/video clips provided.

Thank you for this referral. If the clinical or image interpretation does not parallel your findings or if I can be of any further assistance please contact me.

Nele Eley, DVM, Dr. med. vet., DipECVDI
European Specialist in Veterinary Diagnostic Imaging, Cert. Radiology,
Senior lecturer University of Giessen, Germany, Veterinary Faculty, Department of Radiology
Nele.Eley@sonopath.com