



PATIENT

Soleil Perez

SPECIES

Canine

BREED

Goldendoodle

SEX

SF

AGE

1 Year, 4 Months

INTERPRETED BY

Nele Eley, DVM
Dr. med. Vet. DipECVDI

HOSPITAL NAME

DPC Veterinary
Hospital

REFERRING VET

Ward

INVOICE

54719

DATE

10-19-22

PRESENTING CLINICAL SIGNS

Reason for Visit: vomiting History: 1.5 yr old sf goldendoodle presenting for vomiting. p threw up twice at about 5am this morning what looked like hair balls. o states p has been licking and biting her fur off of both front arms and feels it has to do with anxiety. Then at 7:30am p vomited 3 small piles of bright red blood. o states she gave p a dime sized turkey treat last night that p doesnt usually get but otherwise nothing has changed.

RADIOGRAPHIC STUDY OF THE ABDOMEN

Right lateral and ventrodorsal views totaling 2 images available for review.

RADIOGRAPHIC FINDINGS

The patient is in thin body condition.

The abdominal serosal detail is maintained.

There is moderate generalized gastrointestinal aerophagia noted.

The stomach reveals no evidence of radiopaque foreign material, abnormal dilation, or malpositioning.

The small intestinal loops present mild generalized dilation with gas and are turgid in appearance.

A moderate amount of fecal matter is seen within the colon.

RADIOGRAPHIC DIAGNOSIS

- Gastrointestinal maldigestion pattern.

INTERPRETATION OF THE FINDINGS & FURTHER RECOMMENDATIONS

The radiographic signs are highly suggestive for functional/paralytic ileus with potential for underlying gastroenteropathy. No direct signs for mechanical obstruction are seen. Further definition by means of abdominal ultrasound should be considered in case of persisting clinical signs.



PATIENT

Soleil Perez

SPECIES

Canine

BREED

Goldendoodle

SEX

SF

AGE

1 Year, 4 Months

INTERPRETED BY

Nele Eley, DVM
Dr. med. Vet. DipECVDI

HOSPITAL NAME

DPC Veterinary
Hospital

REFERRING VET

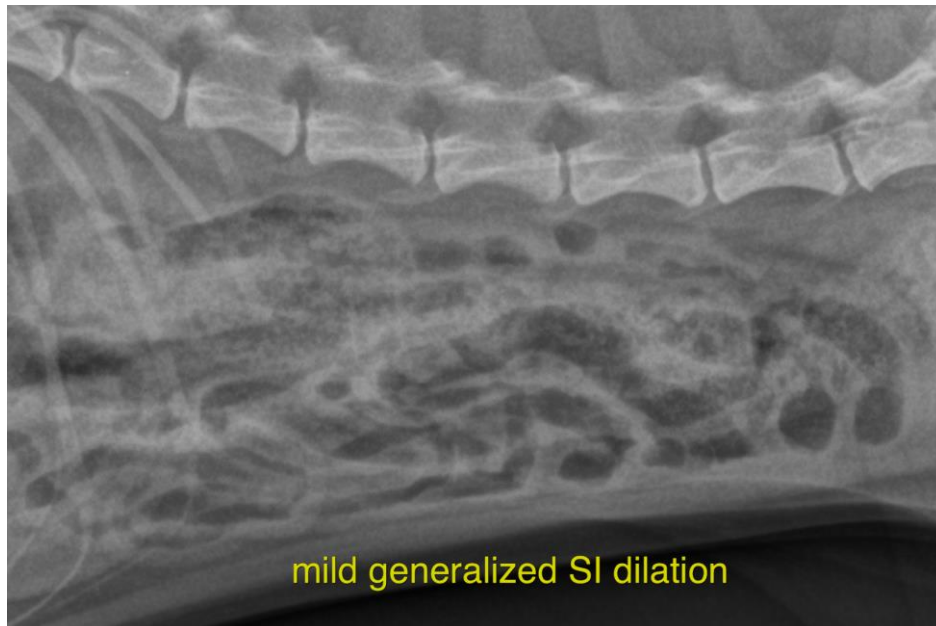
Ward

INVOICE

54719

DATE

10-19-22



The information and recommendations provided are based on the images presented by the referring veterinarian/sonographer. No evaluation can be communicated regarding pathology that was not visible in the image/video clips provided.

Thank you for this referral. If the clinical or image interpretation does not parallel your findings or if I can be of any further assistance please contact me.

Nele Eley, DVM, Dr. med. vet., DipECVDI
European Specialist in Veterinary Diagnostic Imaging, Cert. Radiology,
Senior lecturer University of Giessen, Germany, Veterinary Faculty, Department of Radiology
Nele.Eley@sonopath.com