



PATIENT

Frankie Lally

PRESENTING CLINICAL SIGNS

Chronic lameness right rear leg. No pain elicited

SPECIES

K9

RADIOGRAPHIC STUDY OF THE PELVIS & STIFLES

Lateral and ventrodorsal views of the pelvis and mediolateral neutral and 90 degrees flexed views of both stifles totaling 7 images available for review.

BREED

Mini Australian
Shepherd

RADIOGRAPHIC FINDINGS

Pelvis

The lumbosacral junction and lumbar spine present within normal limits.

The pelvic bones present within the expected limits and bilaterally symmetric.

SEX

MN

No evidence of coxofemoral joint dysplasia, osteoarthritic changes, or traumatic osseous injury is seen.

There is moderate atrophy of the right hind limb musculature.

AGE

5 Years, 11 Months

Stifles

The radiographic presentation of the stifle joints is within age related normal limits. There is no evidence of significant articular swelling, cranial thrust of the tibia, subchondral bone defects, or osteoarthritic changes.

INTERPRETED BY

Nele Eley, DVM
Dr. med. Vet. DipECVDI

RADIOGRAPHIC DIAGNOSIS

- Moderate atrophy of the right hind limb musculature: disuse versus neurogenic.
- Normal radiographic appearance of the coxofemoral and stifle joints.

HOSPITAL NAME

Blairstown Animal
Hospital

INTERPRETATION OF THE FINDINGS & FURTHER RECOMMENDATIONS

The radiographic examination of the stifles and pelvis did not reveal evidence of osseous or articular pathology in the pelvis, coxofemoral joints, and/or stifle joints. Based on the negative radiographic findings, musculotendinopathy with chronic disuse of the right hind limb or neurologic disease with neurogenic muscle atrophy appear to be likely as causes of the muscle loss in the right hind limb and source of the lameness.

REFERRING VET

Dr. Summers

INVOICE

54712

DATE

10-19-22



PATIENT

Frankie Lally

SPECIES

K9

BREED

Mini Australian
Shepherd

SEX

MN

AGE

5 Years, 11 Months

INTERPRETED BY

Nele Eley, DVM
Dr. med. Vet. DipECVDI

HOSPITAL NAME

Blairstown Animal
Hospital

REFERRING VET

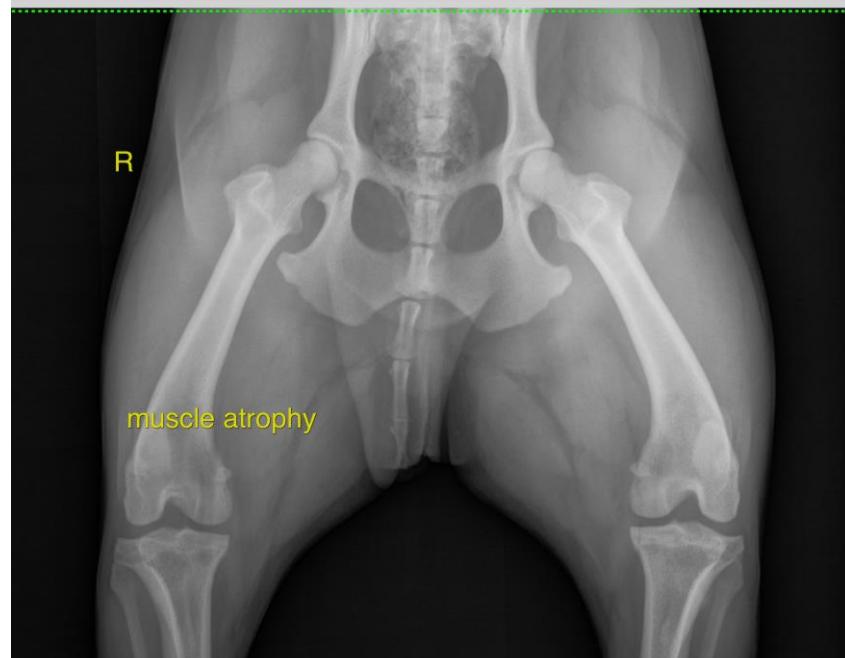
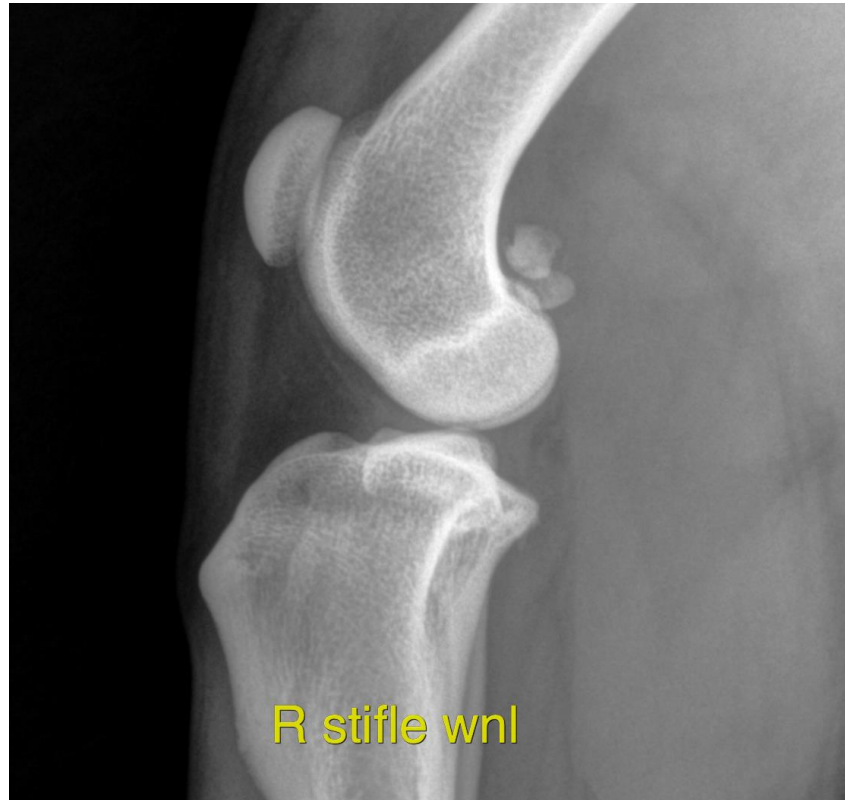Dr. Summers

INVOICE

54712

DATE

10-19-22





PATIENT

Frankie Lally

The information and recommendations provided are based on the images presented by the referring veterinarian/sonographer. No evaluation can be communicated regarding pathology that was not visible in the image/video clips provided.

Thank you for this referral. If the clinical or image interpretation does not parallel your findings or if I can be of any further assistance please contact me.

SPECIES

K9

Nele Eley, DVM, Dr. med. vet., DipECVDI
European Specialist in Veterinary Diagnostic Imaging, Cert. Radiology,
Senior lecturer University of Giessen, Germany, Veterinary Faculty, Department of Radiology
Nele.Eley@sonopath.com

BREED

Mini Australian
Shepherd

SEX

MN

AGE

5 Years, 11 Months

INTERPRETED BY

Nele Eley, DVM
Dr. med. Vet. DipECVDI

HOSPITAL NAME

Blairstown Animal
Hospital

REFERRING VET

Dr. Summers

INVOICE

54712

DATE

10-19-22