

**PATIENT**

Riley Verrico

**PRESENTING CLINICAL SIGNS**

Presented for evaluation for growth removal(s). Exam revealed cardiac murmur.  
Abnormal PE/Chem/CBC/UA Results: BP=189/90

**SPECIES**

Canine

**RADIOGRAPHIC STUDY OF THE THORAX**

Right lateral and ventrodorsal views totaling 2 images available for review.

**BREED**

Pitbull Mix

**RADIOGRAPHIC FINDINGS**

There are mild spondyloses between T4 and T5, T5 and T6, T6 and T7, T7 and T8.

**SEX**

Female Spayed

Mild redundancy of the dorsal tracheal ligament is seen in the caudocervical trachea and considered incidental.

The vertebral heart score is 10.4. No evidence of overall enlargement of the cardiac silhouette and no specific chamber enlargement is noted. The pulmonary vasculature presents within normal limits.

**AGE**

9 Years

The degree of pulmonary inflation is fair to moderate. A mild generalized bronchointerstitial pattern with even distribution is noted throughout the lung and considered within age related normal limits.

**INTERPRETED BY**

Nele Eley, DVM  
Dr. med. Vet. DipECVDI

The cranioventral mediastinal reflection is prominent. No evidence of pathologic mediastinal widening or mediastinal lymphadenomegaly is seen.

**RADIOGRAPHIC DIAGNOSIS**

- Normal age related thorax.

**HOSPITAL NAME**

Long Valley Animal  
Hospital

**INTERPRETATION OF THE FINDINGS & FURTHER RECOMMENDATIONS**

The radiographic study reveals no specific chamber enlargement of the heart. No evidence of a vascular pattern or congestive heart failure is seen, yet presence of functional abnormality and valvular insufficiencies cannot be ruled out. A full cardiac echo could be considered for further definition in this patient.

**REFERRING VET**

Russell Earl

**INVOICE**

47858

**DATE**

10-19-21



**PATIENT**

Riley Verrico

**SPECIES**

Canine

**BREED**

Pitbull Mix

**SEX**

Female Spayed

**AGE**

9 Years

**INTERPRETED BY**

Nele Eley, DVM  
Dr. med. Vet. DipECVDI

**HOSPITAL NAME**

Long Valley Animal  
Hospital

**REFERRING VET**

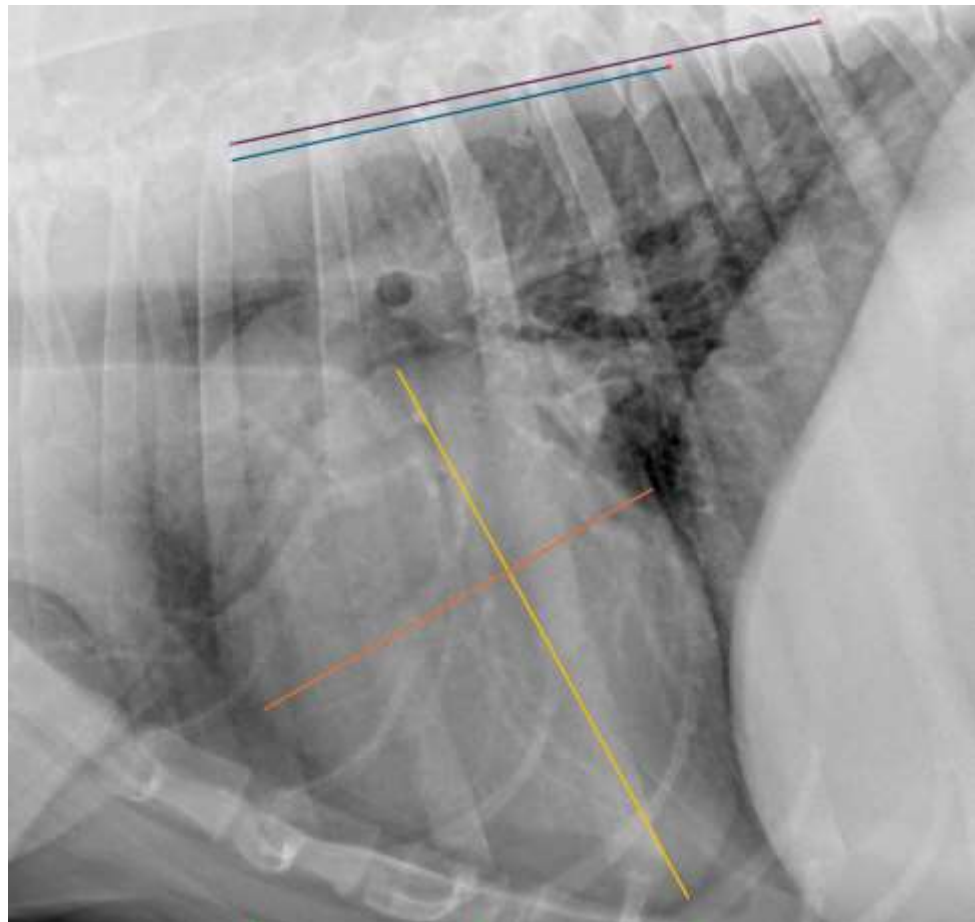
Russell Earl

**INVOICE**

47858

**DATE**

10-19-21



The information and recommendations provided are based on the images presented by the referring veterinarian. No evaluation can be communicated regarding pathology that was not visible in the image/video clips provided.

Thank you for this referral. If the clinical or image interpretation does not parallel your findings or if I can be of any further assistance please contact me.

**Nele Eley**, DVM, Dr. med. vet., DipECVDI  
European Specialist in Veterinary Diagnostic Imaging, Cert. Radiology,  
Senior lecturer University of Giessen, Germany, Veterinary Faculty, Department of Radiology  
Nele.Eley@sonopath.com