

**PATIENT**

Luna Gelok

**PRESENTING CLINICAL SIGNS**

sudden onset of coughing/gagging  
Abnormal PE/Chem/CBC/UA Results: no abnormal lung/heart sound BW revealed azotemia, hyperglycemia, stress leukogram, dehydration, rest WNL, SDMA is pending

**SPECIES**

Feline

**RADIOGRAPHIC STUDY OF THE THORAX**

Right lateral and ventrodorsal whole body views totaling 2 images available for review.

**BREED**

DSH

Thoracic read requested.

**RADIOGRAPHIC FINDINGS**

Mild spondyloses are present within the thoracic spine between T8/9 and T9/10.

**SEX**

Female Spayed

There is mild esophageal aerophagia.

A mild generalized bronchial lung pattern is noted with even distribution throughout the lung. Mild atelectasis of the right middle lobe appears to be present. Occasional peribronchial cuffing is seen.

**AGE**

12 Years

The course and width of the trachea are considered within normal limits.

There is no evidence of mediastinal lymphadenomegaly or other pathologic mediastinal widening.

**INTERPRETED BY**

Nele Eley, DVM  
Dr. med. Vet. DipECVDF

The radiographic presentation of the cardiac silhouette and pulmonary vasculature is considered within normal limits.

**RADIOGRAPHIC DIAGNOSIS**

- Mild active lower airway pattern.
- No radiographic evidence of cardiovascular pathology.
- No evidence of mediastinal lymphadenomegaly.

**HOSPITAL NAME**

St. Catharine's Animal  
Hospital

**INTERPRETATION OF THE FINDINGS & FURTHER RECOMMENDATIONS****REFERRING VET**

Dr. Masoud

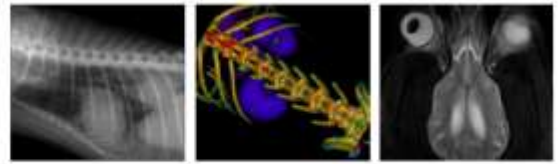
The radiographic findings suggest potential for active lower airway disease. Consider recurrent allergic feline lower airway syndrome a potential versus infectious bronchitis such as viral, bacterial, parasitic, or protozoal. Upper airway involvement cannot be ruled out and a clinical trial of treatment for bronchitis should be weighed against further definition by means of airway endoscopy with airway sampling.

**INVOICE**

47860

**DATE**

10-19-21



**PATIENT**

Luna Gelok

The information and recommendations provided are based on the images presented by the referring veterinarian. No evaluation can be communicated regarding pathology that was not visible in the image/video clips provided.

Thank you for this referral. If the clinical or image interpretation does not parallel your findings or if I can be of any further assistance please contact me.

**SPECIES**

Feline

**Nele Eley**, DVM, Dr. med. vet., DipECVDI  
European Specialist in Veterinary Diagnostic Imaging, Cert. Radiology,  
Senior lecturer University of Giessen, Germany, Veterinary Faculty, Department of Radiology  
Nele.Eley@sonopath.com

**BREED**

DSH

**SEX**

Female Spayed

**AGE**

12 Years

**INTERPRETED BY**

Nele Eley, DVM  
Dr. med. Vet. DipECVDI

**HOSPITAL NAME**

St. Catharine's Animal  
Hospital

**REFERRING VET**

Dr. Masoud

**INVOICE**

47860

**DATE**

10-19-21