



**PATIENT PRESENTING CLINICAL SIGNS**

Tank Pally Concerns for neoplasia of the thorax

**COMPUTED TOMOGRAPHIC STUDY OF THE THORAX**

**SPECIES**

Plain and post contrast studies of the thorax available for review.

Canine

**COMPUTED TOMOGRAPHIC FINDINGS**

**BREED**

There are multiple hemivertebrae within the thoracic spine.

French Bulldog

Multifocal spondylosis deformans is noted.

**SEX**

A large ovoid soft tissue attenuating mass with heterogeneous enhancement is seen in the perihilar cranial aspect of the left caudal lung lobe. The mass causes compression of the main lobar bronchus. One larger and multiple smaller interstitial pulmonary nodules are distributed throughout the remainder of the lung. There is a multifocal peribronchial interstitial pulmonary infiltrate.

MC

**AGE**

Multiple moderate to severe tracheobronchial and cranial mediastinal lymphadenomegaly with the lymph nodes measuring up to 2.5 cm in diameter are noted.

10 Years

Generalized tracheal hypoplasia is seen however considered within the breed related normal limits.

**COMPUTED TOMOGRAPHIC DIAGNOSIS**

**INTERPRETED BY**

Nele Eley (Ondreka),  
DVM Dr. med. vet.,  
DipECVDI

- Large pulmonary mass and multiple interstitial pulmonary nodules.
- Multiple moderate to severe cranial mediastinal and tracheobronchial lymphadenomegaly.
- Peribronchial interstitial infiltrate.
- Multiple congenital vertebral malformation.
- Multiple spondyloses.
- Tracheal hypoplasia.

**HOSPITAL NAME**

Mobile Pet Imaging  
CFL

**INTERPRETATION OF FINDINGS & FURTHER RECOMMENDATIONS**

The CT study reveals a large pulmonary mass within the left caudal lung lobe. Multiple additional pulmonary nodules are noted as well as concurrent tracheobronchial and cranial mediastinal lymphadenomegaly. Secondary neoplasia of the lung such as lymphosarcoma, histiocytic sarcoma, or other soft tissue sarcoma is considered more likely than primary neoplasia of the lung such as bronchial carcinoma owing to the multifocal occurrence and mediastinal lymph node involvement. However, primary neoplasia of the lung with metastases to the lymph nodes and pulmonary interstitium, as well as metastases of another primary tumor are theoretical potentials too.

**REFERRING VET**

Anaelys Concepcion

**INVOICE**

54678

**DATE**

10-18-22



**PATIENT**

Tank Pally

**SPECIES**

Canine

**BREED**

French Bulldog

**SEX**

MC

**AGE**

10 Years

**INTERPRETED BY**

Nele Eley (Ondreka),  
DVM Dr. med. vet.,  
DipECVDI

**HOSPITAL NAME**

Mobile Pet Imaging  
CFL

**REFERRING VET**

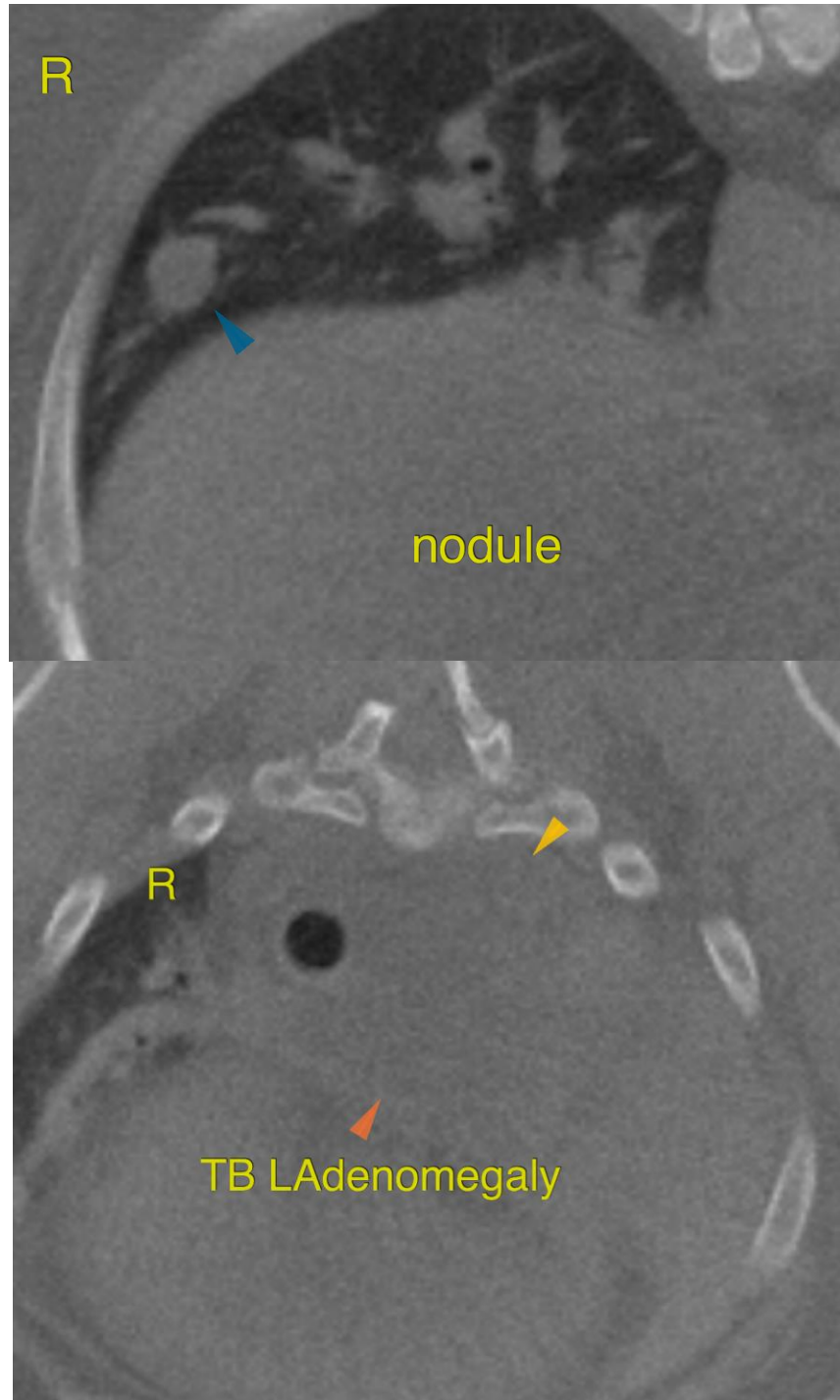
Anaelys Concepcion

**INVOICE**

54678

**DATE**

10-18-22





**PATIENT**

Tank Pally

**SPECIES**

Canine

**BREED**

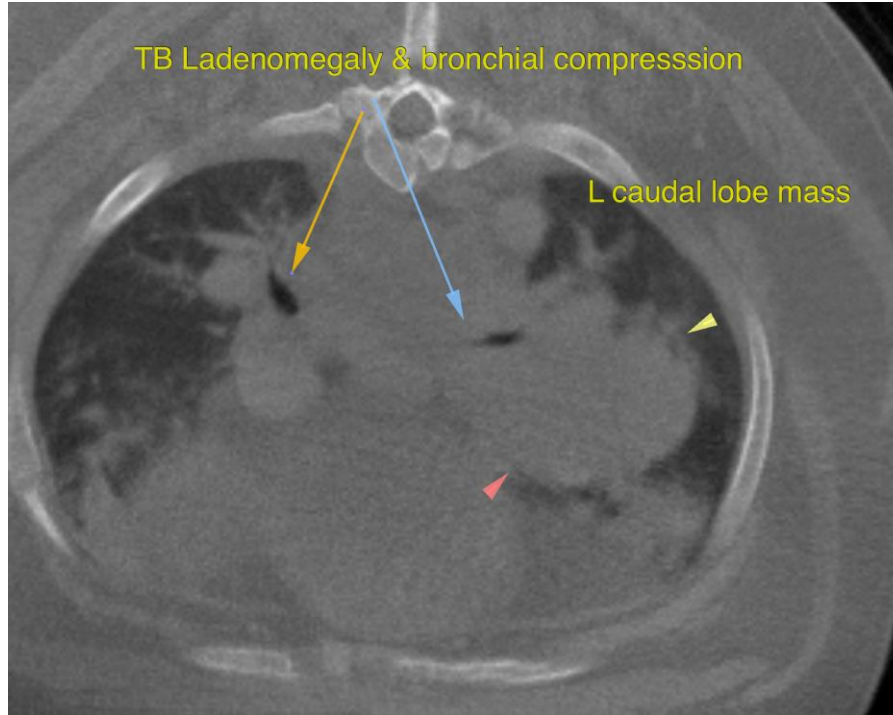
French Bulldog

**SEX**

MC

**AGE**

10 Years



**INTERPRETED BY**

Nele Eley (Ondreka),  
DVM Dr. med. vet.,  
DipECVDI

The information and recommendations provided are based on the images presented by the referring veterinarian. No evaluation can be communicated regarding pathology that was not visible in the image/video clips provided.

Thank you for this referral. If the clinical or image interpretation does not parallel your findings or if I can be of any further assistance please contact me.

**HOSPITAL NAME**

Mobile Pet Imaging  
CFL

**Nele Eley (Ondreka)**, DVM, Dr. med. vet., DipECVDI  
European Specialist in Veterinary Diagnostic Imaging, Cert. Radiology,  
Senior lecturer University of Giessen/Germany, Veterinary Faculty, Department of Radiology.  
Nele.Eley@sonopath.com

**REFERRING VET**

Anaelys Concepcion

**INVOICE**

54678

**DATE**

10-18-22