



**PATIENT**

George Chudiak

**PRESENTING CLINICAL SIGNS**

RF lameness Aug 2019, resolved within 2 days with Deramaxx. Since Nov 2020, has had on and off lameness RF. when it occurs, he knuckles when standing still, then has pronounced lameness. Has old RF styloid injury, mild OA in elbows, tendon calcification suspect in lebow extensors on rads.

**SPECIES**

Canine

Abnormal PE/Chem/CBC/UA Results: Mild mononuclear inflammation on arthrocentesis both R elbow and carpus. Mild atrophy to R infra and supraspinatus, otherwise normal exam

**BREED**

Dogo Argentino X

**ULTRASONOGRAPHIC FINDINGS**

**Left Shoulder**

8.5mm is the maximum thickness of the left supraspinatus tendon. There is mild internal echoarchitectural remodeling of the left supraspinatus with non-shadowing echogenic foci. Mild deviation of the transverse ligament of the biceps tendon is seen.

**SEX**

MN

The biceps tendon presents a mild amount of anechoic effusion and mild generalized synovial swelling. Early exostosis is seen within the intertubercular groove.

**AGE**

3 Years

The left teres minor and infraspinatus present within normal limits.

Visible periarticular margins present within normal limits. No structural abnormality is seen in the medial joint compartment.

**INTERPRETED BY**

Nele Eley, DVM  
Dr. med. Vet. DipECVDI

**Right Shoulder**

Moderate echoarchitectural remodeling with multiple echogenic foci are seen in the right supraspinatus. The supraspinatus thickness is 9mm.

Mild to moderate deviation of the transverse ligament of the biceps tendon is seen.

**HOSPITAL NAME**

Cedarview Animal  
Hospital

The biceps tendon presents a mild amount of anechoic effusion and moderate generalized synovial swelling. Early exostosis is seen within the intertubercular groove.

The right teres minor and infraspinatus present within normal limits.

**REFERRING VET**

Nigel Gumley

Visible periarticular margins present within normal limits. No structural abnormality is seen in the medial joint compartment.

The extensor origin is partially seen and presents mild enthesophytosis with mild swelling and heterogeneity of the extensor origin.

**INVOICE**

47843

**ULTRASONOGRAPHIC DIAGNOSIS**

- Mild bilateral biceps tenosynovitis, right more than left, with bilateral supraspinatus tendinopathy and emerging impingement.
- Mild chronic right extensor enthesopathy.

**DATE**

10-18-21



**PATIENT**

George Chudiak

**SPECIES**

Canine

**BREED**

Dogo Argentino X

**SEX**

MN

**AGE**

3 Years

**INTERPRETED BY**

Nele Eley, DVM  
Dr. med. Vet. DipECVDI

**HOSPITAL NAME**

Cedarview Animal  
Hospital

**REFERRING VET**

Nigel Gumley

**INVOICE**

47843

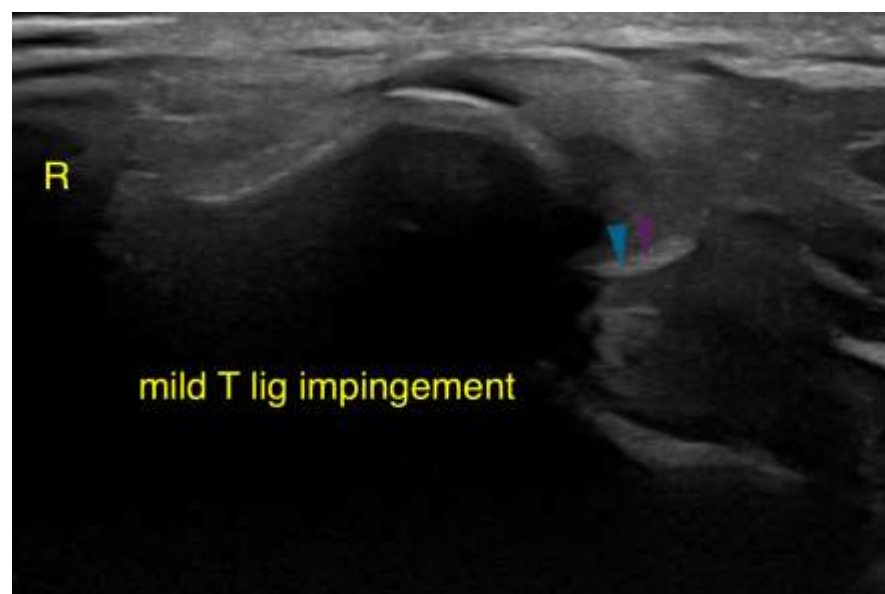
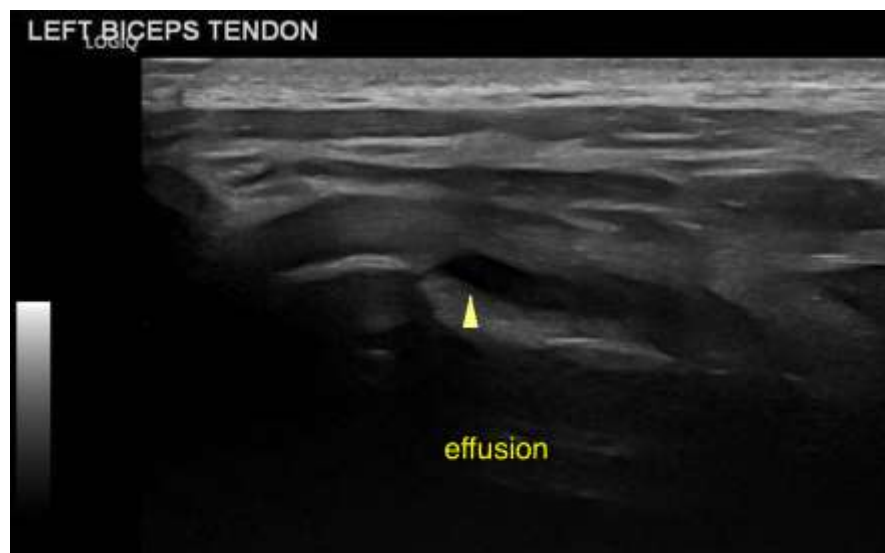
**DATE**

10-18-21

**INTERPRETATION OF THE FINDINGS & FURTHER RECOMMENDATIONS**

The ultrasonographic study of the shoulders reveals chronic mild bilateral biceps tenosynovitis. The changes are more pronounced on the right when compared with the left side. There also is early supraspinatus tendinopathy with emerging impingement on the transverse ligament; however, it appears rather unlikely that the supraspinatus tendinopathy is the cause of the biceps tenosynovitis, at least at this stage with the very subtle changes and mild deviation of the transverse ligament.

The study of the extensor origin is limited. However, the findings do suggest presence of mild chronic extensor enthesopathy.





**PATIENT**

George Chudiak

The information and recommendations provided are based on the images presented by the referring veterinarian. No evaluation can be communicated regarding pathology that was not visible in the image/video clips provided.

**SPECIES**

Canine

Thank you for this referral. If the clinical or image interpretation does not parallel your findings or if I can be of any further assistance please contact me.

**BREED**

Dogo Argentino X

**Nele Eley**, DVM, Dr. med. vet., DipECVDI  
European Specialist in Veterinary Diagnostic Imaging, Cert. Radiology,  
Senior lecturer University of Giessen, Germany, Veterinary Faculty, Department of Radiology  
Nele.Eley@sonopath.com

**SEX**

MN

**AGE**

3 Years

**INTERPRETED BY**

Nele Eley, DVM  
Dr. med. Vet. DipECVDI

**HOSPITAL NAME**

Cedarview Animal  
Hospital

**REFERRING VET**

Nigel Gumley

**INVOICE**

47843

**DATE**

10-18-21