


**PATIENT PRESENTING CLINICAL SIGNS**

**Bane O'Brien** Bane has a history of intervertebral disc disease diagnosed years ago via MRI. His ataxia had resolved and he had been doing well for years. He started to show signs of ataxia in September 2021. No response to steroids. Has been persistent since first presented in early September. Drags hind limb paws at times.

**SPECIES**

Canine

**BREED**

Pit Bull X

Abnormal PE/Chem/CBC/UA Results: BAR, mm pink/moist crt <2s; BCS 4/9. Heart and lungs auscult wnl; ataxia in the hind end. Proprioceptive deficits. Normal range of motion of neck. No obvious pain elicited on palpation of thoracolumbar vertebrae? P has had weight loss. cbc unremarkable; chemistry ALT 237; AST 33; ALP 1,379; GGT 24; Total T4 0.7; Free T4 (ng/dL) 0.6; Free T4 (pmol/L) 7.7; cTSH 0.93 [0.05 - 0.42 ng/mL] Fast scan abdominal ultrasound unremarkable. Suspect that the liver enzyme elevations are from the steroids. We will recheck after tapering.

**COMPUTED TOMOGRAPHIC STUDY OF THE CERVICAL & THORACOLUMBAR SPINE**
**SEX**

Plain and post-IV studies provided for review.

Neutered Male

**COMPUTED TOMOGRAPHIC FINDINGS**
**AGE**

10 Years

Number and general anatomy of the cervical vertebrae present within normal limits. Moderate to severe intervertebral disc space collapse with ventral tapering is seen between the 6<sup>th</sup> and 7<sup>th</sup> cervical vertebrae. The neighboring vertebral endplates present sclerosis and osseous remodeling with a mild amount of ventral new bone formation. There appears to be herniation of iso-to faintly hyperattenuating intervertebral disc material into the ventral epidural space. However, the material/hernia cannot be delineated against the dural tube and spinal cord. No evidence of aggressive bone lesions is seen. Early spondyloses are present at T1/2, T3/4.

**INTERPRETED BY**

Nele Eley (Ondreka),  
 DVM Dr. med. vet.,  
 DipECVDI

Sever intervertebral disc space collapse and intervertebral vacuum phenomenon is seen at T13/L1. There is step formation and stenosis of the vertebral canal pivoting over the intervertebral disc space T13/L1 with mild ventral subluxation and kyphosis of the cranial lumbar spine with respect to the caudal thoracic spine. Kyphosis angle is approximately 10 degrees. Moreover, partially mineralized extrusion of intervertebral disc material with organized appearance is seen in the left and ventral epidural space at T13/L1. The extrusion presents mild left-sided neuroforaminal extension.

**HOSPITAL NAME**

AMC of Mt. Pleasant

Subluxation of the vertebral facets with interarcuate space widening is seen, and there is a severe ventrally bridging spondylosis. The vertebral canal cross sectional area is reduced by more than 50% of its original width. Severe deviation and compression of the spinal cord are noted. Moderate spondylosis is present between L2 and L3 with moderate partially mineralized intervertebral disc extrusion, which is mainly situated within the left ventral epidural space. Mild to moderate disc protrusions are also seen at L6/7 and L7/S1.

**REFERRING VET**

Dr. Fenamore

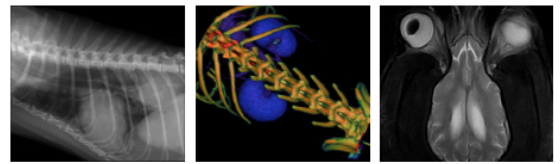
**COMPUTED TOMOGRAPHIC DIAGNOSIS**
**INVOICE**

26354

**DATE**

10/18/21

- Chronic intervertebral disc disease with intervertebral disc space collapse, vertebral endplate sclerosis, and spondylosis deformans C6/7.
- Early spondyloses T1/2 and T3/4
- Severe chronic spinal cord compression T13/L1, secondary to chronic compressive extrusion and ventral subluxation with kyphosis in the thoracolumbar junction
- Moderate compressive myelopathy with signs of chronicity, secondary to intervertebral disc extrusion L2/3



**PATIENT** • Mild to moderate protrusions L6/7 and L7/S1

Bane O'Brien

**INTERPRETATION OF FINDINGS & FURTHER RECOMMENDATIONS**

**SPECIES**

Canine

Severe spinal cord compression is seen at the thoracolumbar junction. There is kyphosis, ventral subluxation, and presumably chronic intervertebral disc extrusion and T13/L1. Chronic spinal cord compression has to be considered lightly and may well correlate with the patient's clinical signs. A second site of moderate chronic compression appears to be present at L2/3 within the cranial lumbar spine. The lumbosacral stenosis is considered less significant compared to the disc hernias in the thoracolumbar junction and cranial lumbar spine.

**BREED**

Pit Bull X

The CT findings are highly suggestive for intervertebral disc disease with disc hernia in the deep cervical spine at C6/7. The changes do suggest potential for chronic spinal cord compression at this level. However, a CT myelogram or MRI would be required in order to accurately delineate the disc material against the spinal cord and to quantify the degree of spinal cord compression.

**SEX**

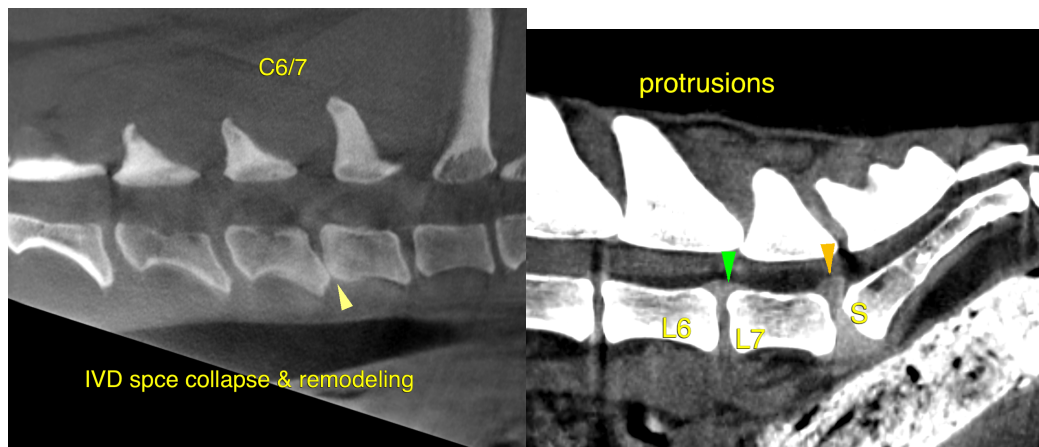
Neutered Male

**AGE**

10 Years

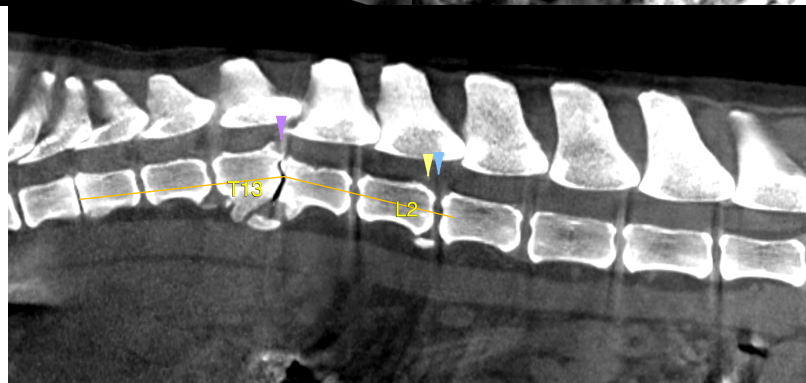
**INTERPRETED BY**

Nele Eley (Ondreka),  
DVM Dr. med. vet.,  
DipECVDD



**HOSPITAL NAME**

AMC of Mt. Pleasant



**REFERRING VET**

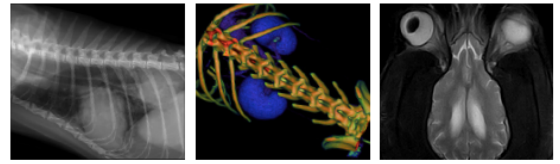
Dr. Fenamore

**INVOICE**

26354

**DATE**

10/18/21



**PATIENT**

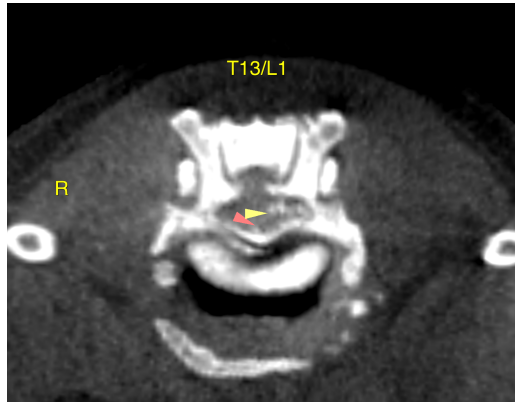
Bane O'Brien

**SPECIES**

Canine

**BREED**

Pit Bull X



**SEX**

Neutered Male

**AGE**

10 Years

The information and recommendations provided are based on the images presented by the referring veterinarian. No evaluation can be communicated regarding pathology that was not visible in the image/video clips provided.

Thank you for this referral. If the clinical or image interpretation does not parallel your findings or if I can be of any further assistance please contact me.

**Nele Eley (Ondreka)**, DVM, Dr. med. vet., DipECVDI  
European Specialist in Veterinary Diagnostic Imaging, Cert. Radiology,  
Senior lecturer University of Giessen/Germany, Veterinary Faculty, Department of Radiology.  
Nele.Eley@sonopath.com

**INTERPRETED BY**

Nele Eley (Ondreka),  
DVM Dr. med. vet.,  
DipECVDI

**HOSPITAL NAME**

AMC of Mt. Pleasant

**REFERRING VET**

Dr. Fenamore

**INVOICE**

26354

**DATE**

10/18/21