



**PATIENT**

P.V. Sandulak

**PRESENTING CLINICAL SIGNS**

vomiting, diarrhea, lethargy  
 Abnormal PE/Chem/CBC/UA Results: QAR, lethargic dehydration- 5%, severely distended abdomen elevated fPL, severe azotemia, urinalysis- revealed low sp. gravity, proteinuria.

**SPECIES**

Feline

**RADIOGRAPHIC STUDY OF THE THORAX & ABDOMEN**

Right/left lateral and ventrodorsal whole body views totaling 3 images available for review.

**BREED**

Domestic Shorthair

**RADIOGRAPHIC FINDINGS**

**Thorax**

Multiple spondyloses are seen within the mid thoracic spine.

**SEX**

Male

The degree of pulmonary inflation is moderate. A mild generalized bronchointerstitial lung pattern is noted and evenly distributed throughout the lung. Plate-like atelectasis of the left cranial lung lobe is seen on the orthogonal view.

**AGE**

17 Years

There is no evidence of pleural effusion and no evidence of mediastinal widening.

The radiographic presentation of the cardiac silhouette is considered within normal limits.

**INTERPRETED BY**

Nele Eley, DVM  
 Dr. med. Vet. DipECVDI

**Abdomen**

The abdominal serosal detail is maintained except for an area medial to the splenic head coinciding with the anatomic position of the left limb of the pancreas.

Mild gastric aerophagia is noted.

**HOSPITAL NAME**

St. Catherine's Animal  
 Hospital

The small intestinal loops present mild and even dilation with fluid and gas content. No evidence of plication, segmental dilation, or radiopaque foreign material is seen.

The colon appears to contain a moderate amount of fluid content.

**REFERRING VET**

Dr. Jui Gokhale

Linear mineralizations superimpose with the renal diverticuli of both kidneys.

The urinary bladder presents within normal limits.

There is moderate degenerative lumbosacral stenosis.

**INVOICE**

54642

**RADIOGRAPHIC DIAGNOSIS**

- Suspect pancreatopathy.
- Suspect functional small intestinal ileus.
- Bilateral hypercalcemic nephropathy.
- Normal age related lung.
- No radiographic evidence of cardiovascular pathology.
- Multiple spondyloses.

**DATE**

10-17-22



**PATIENT**

P.V. Sandulak

- Degenerative lumbosacral stenosis.

**INTERPRETATION OF THE FINDINGS & FURTHER RECOMMENDATIONS**

The diagnostic accuracy of radiographs regarding pancreatic pathology is limited yet the findings do support the potential of pancreatopathy which may also be the underlying cause of the presumed functional ileus.

**SPECIES**

Feline

No evidence of mechanical obstruction of the small intestine is seen yet the generalized mild dilation of the small intestine is suggesting functional ileus which is further supported by the presence of fluid content within the colon.

**BREED**

Domestic Shorthair

Further definition by means of full abdominal ultrasound could be pursued if not performed yet.

**SEX**

Male

**AGE**

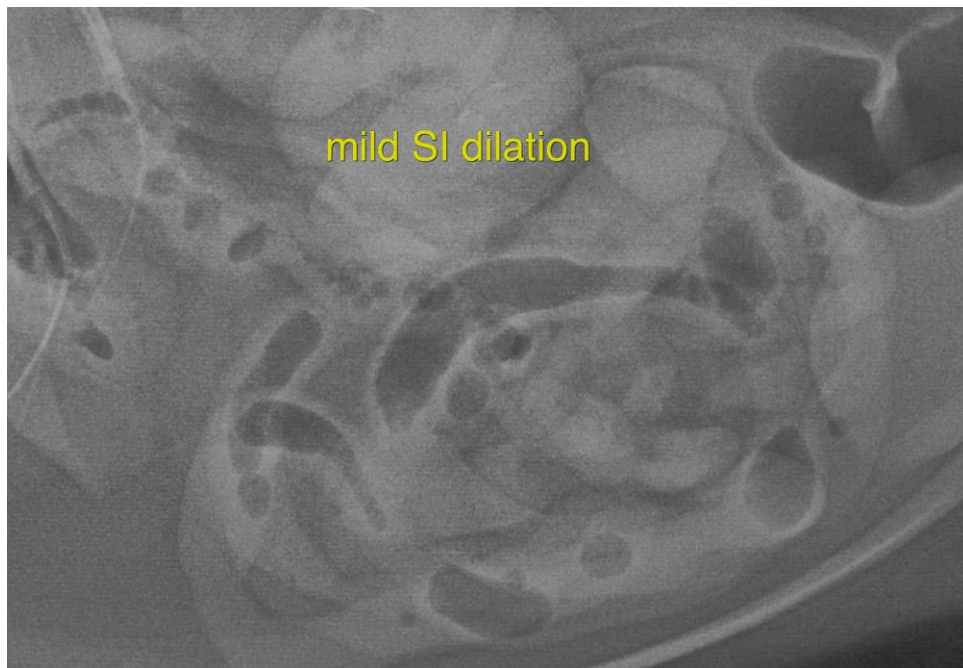
17 Years

**INTERPRETED BY**

Nele Eley, DVM  
Dr. med. Vet. DipECVDI

**HOSPITAL NAME**

St. Catherine's Animal  
Hospital



**REFERRING VET**

Dr. Jui Gokhale

The information and recommendations provided are based on the images presented by the referring veterinarian/sonographer. No evaluation can be communicated regarding pathology that was not visible in the image/video clips provided.

**INVOICE**

54642

Thank you for this referral. If the clinical or image interpretation does not parallel your findings or if I can be of any further assistance please contact me.

**DATE**

10-17-22

**Nele Eley**, DVM, Dr. med. vet., DipECVDI  
European Specialist in Veterinary Diagnostic Imaging, Cert. Radiology,  
Senior lecturer University of Giessen, Germany, Veterinary Faculty, Department of Radiology  
Nele.Eley@sonopath.com