

**PATIENT**

Murphy Downey

**PRESENTING CLINICAL SIGNS**

Murphy has been having diarrhea and vomiting. They are unsure if he got into something and ate it, but the first vomiting looked strange and had white plastic/rubber looking pieces in there. The stool is watery and yellowish/brown. Linda withheld food for 24 hours and then started giving Murphy rice. The diarrhea started again. He is having to go three times daily and Linda says he is now straining.

**SPECIES**

Canine

Abnormal PE/Chem/CBC/UA Results: MILD DEHYDRATION MILDLY TACKY - mucus membranes Rectal examination NORMAL. MILD TARTAR ONLY. oral exam

**BREED**

Golden Retriever Mix

**RADIOGRAPHIC STUDY OF THE ABDOMEN**

Lateral and ventrodorsal views of the abdomen totaling 4 images available for review. Motion related image blur is noted on the available images.

**SEX**

Neutered Male

The abdominal serosal detail appears to be maintained.

**AGE**

1 Year, 3 Months

The small intestinal loops are evenly distributed throughout the mid abdomen with no evidence of abnormal dilation, plication, or radiopaque foreign material.

Gas dilated intestinal loops are seen and can be assigned to the cecum and descending colon.

Mild gastric aerophagia is noted. I cannot identify evidence of radiopaque foreign material.

**INTERPRETED BY**

Nele Eley, DVM  
Dr. med. Vet. DipECVDI

The urinary bladder is moderately distended. Mild dorsal deviation of the descending colon is noted.

**RADIOGRAPHIC DIAGNOSIS**

- Intestinal maldigestion pattern – no radiographic evidence of mechanical ileus.

**HOSPITAL NAME**

Elizabeth Animal  
Hospital

**INTERPRETATION OF THE FINDINGS & FURTHER RECOMMENDATIONS**

The radiographic study reveals no direct signs of mechanical small intestinal ileus. No radiopaque foreign material can be identified. The findings support the potential of functional ileus. Subileus cannot be ruled out entirely and further definition by means of abdominal ultrasound should be considered in case of pertinent clinical signs.

**REFERRING VET**

Leon Anderson, DVM

**INVOICE**

54630

**DATE**

10-15-22



**PATIENT**

Murphy Downey

**SPECIES**

Canine

**BREED**

Golden Retriever Mix

**SEX**

Neutered Male

**AGE**

1 Year, 3 Months

**INTERPRETED BY**

Nele Eley, DVM  
Dr. med. Vet. DipECVDI

**HOSPITAL NAME**

Elizabeth Animal  
Hospital

**REFERRING VET**

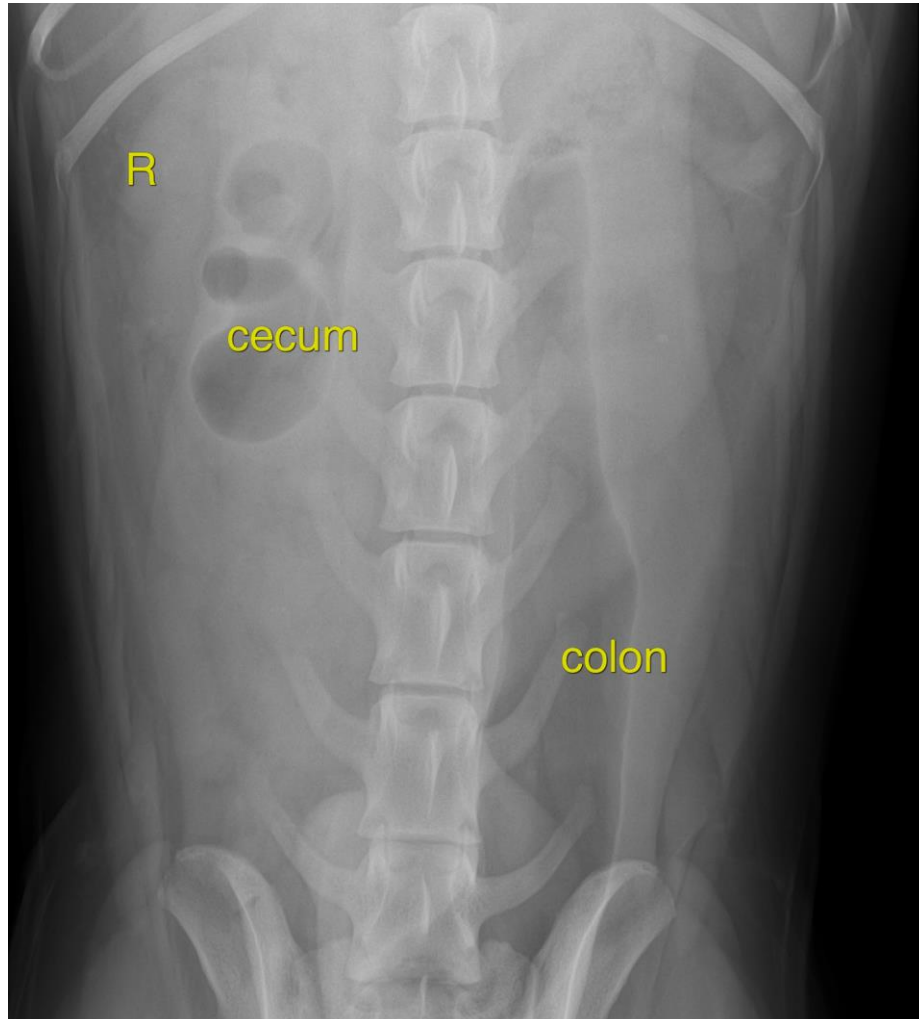
Leon Anderson, DVM

**INVOICE**

54630

**DATE**

10-15-22



The information and recommendations provided are based on the images presented by the referring veterinarian/sonographer. No evaluation can be communicated regarding pathology that was not visible in the image/video clips provided.

Thank you for this referral. If the clinical or image interpretation does not parallel your findings or if I can be of any further assistance please contact me.

**Nele Eley**, DVM, Dr. med. vet., DipECVDI  
European Specialist in Veterinary Diagnostic Imaging, Cert. Radiology,  
Senior lecturer University of Giessen, Germany, Veterinary Faculty, Department of Radiology  
Nele.Eley@sonopath.com