



PATIENT

Sasha Michol Panelli

PRESENTING CLINICAL SIGNS

Patient has what appears to be a seizure 16hrs ago. Has yet to regain ability to stand. Present nystagmus and right side head tilt. Was started on Phenobarbital 30mg BID. Abnormal PE/Chem/CBC/UA Results: CBC --- RBC mild increased HCT mild increased and thrombocytosis CHEM --- ALP and GLU severe increased

SPECIES

Canine

COMPUTED TOMOGRAPHIC STUDY OF THE HEAD

Plain and post contrast studies available for review.

BREED

Shih Tzu

COMPUTED TOMOGRAPHIC FINDINGS

The brain presents no deviation from normal anatomy and symmetry. The grey and white matter distinction and the neuroparenchymal attenuation are as expected. The distribution of contrast enhancement is within normal limits throughout the parenchyma and meninges. The ventricular system is non-dilated and within the limits of the expected volume and symmetry.

SEX

SF

Thin and smoothly folded conchae and turbinates with even smooth mucosal lining. The osseous lining of the nasal cavities is intact.

AGE

12 Years

Both temporomandibular joints present congruent joint spaces with even subchondral bone surfaces and are considered within normal limits.

INTERPRETED BY

Nele Eley, DVM
Dr. med. Vet. DipECVDI

Both tympanic bullae are aerated, the mucosal lining is not seen, the bony wall is smooth and thin. The external auditory meatuses present within normal limits.

The submandibular and medial retropharyngeal lymph nodes are small and elongated with a normal short-to-long-axis-ratio is < 0.5, the attenuation and contrast enhancement pattern is uniform.

HOSPITAL NAME

Veterinary Image Center

The salivary glands present within normal limits.

Overlapping tooth roots are seen in the shortened dental arcades with multifocal periodontal disease.

REFERRING VET

Dr. H. Lidin, DVM

COMPUTED TOMOGRAPHIC DIAGNOSIS

- Normal CT findings of the brain.
- Multifocal periodontal disease.

INTERPRETATION OF THE FINDINGS & FURTHER RECOMMENDATIONS

INVOICE

54618

The CT study did not reveal structural brain pathology. There was no evidence of midline shift, changes in the attenuation, anatomy, or enhancement of the brain and no evidence of ventriculomegaly was seen. Nevertheless, structural brain injury such as inflammatory/ infectious, metabolic/toxic, cerebrovascular, and other cannot be ruled out entirely. The possibility of idiopathic / geriatric vestibular syndrome appears to be a potential consideration as well. The use of csf tap and analysis could be discussed for further definition depending on the clinical context.

DATE

10-14-22



PATIENT

Sasha Michol Panelli

SPECIES

Canine

BREED

Shih Tzu

SEX

SF

AGE

12 Years

INTERPRETED BY

Nele Eley, DVM
Dr. med. Vet. DipECVDI

HOSPITAL NAME

Veterinary Image
Center

REFERRING VET

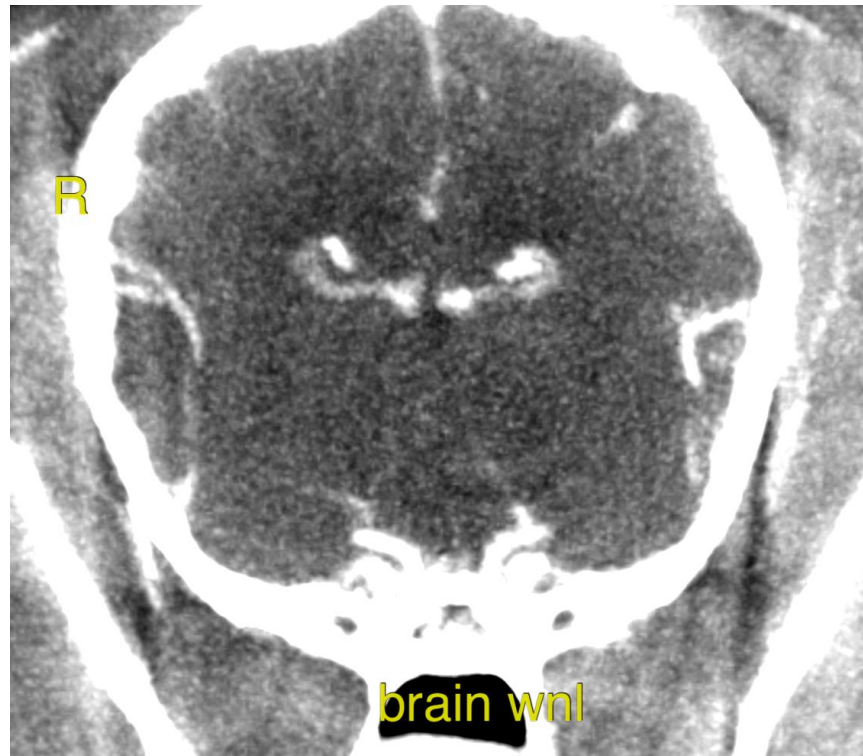
Dr. H. Lidin, DVM

INVOICE

54618

DATE

10-14-22



The information and recommendations provided are based on the images presented by the referring veterinarian/sonographer. No evaluation can be communicated regarding pathology that was not visible in the image/video clips provided.

Thank you for this referral. If the clinical or image interpretation does not parallel your findings or if I can be of any further assistance please contact me.

Nele Eley, DVM, Dr. med. vet., DipECVDI
European Specialist in Veterinary Diagnostic Imaging, Cert. Radiology,
Senior lecturer University of Giessen, Germany, Veterinary Faculty, Department of Radiology
Nele.Eley@sonopath.com