



PATIENT

Onyx Grasso

PRESENTING CLINICAL SIGNS

Pt presented for hip evaluation. Nsf on PE.

SPECIES

Canine

RADIOGRAPHIC STUDY OF THE PELVIS

Ventrodorsal hip extended view and lateral views of the pelvis totaling 4 images available for review.

BREED

GSD

The patient has a broomstick like conformation of the femoral head and neck which is a common anatomic variant in German shepherd dogs.

SEX

M

Both femoral heads are deeply situated within the acetabulum with normal femoral head coverage. No joint space incongruity is seen. There is no evidence of osteoarthritic changes.

The Norberg angles range between 103 and 106 degrees on the left and right side.

The lumbosacral junction presents within normal radiographic limits.

AGE

1 Year

RADIOGRAPHIC DIAGNOSIS

- Normal coxofemoral joint conformation with no evidence of hip dysplasia and/or increased laxity.

INTERPRETED BY

Nele Eley, DVM
Dr. med. Vet. DipECVDI

INTERPRETATION OF THE FINDINGS & FURTHER RECOMMENDATIONS

The radiographic presentation of the coxofemoral joints is considered within normal age and breed related limits. There is no radiographic evidence of canine hip dysplasia or osteoarthritic changes of the hip joints.

HOSPITAL NAME

The Pet Hospital of
Stratford

REFERRING VET

Dr. Claudia Giuliani,
DVM

INVOICE

54617

DATE

10-14-22



PATIENT

Onyx Grasso

SPECIES

Canine

BREED

GSD

SEX

M

AGE

1 Year

INTERPRETED BY

Nele Eley, DVM
Dr. med. Vet. DipECVDI

HOSPITAL NAME

The Pet Hospital of
Stratford

REFERRING VET

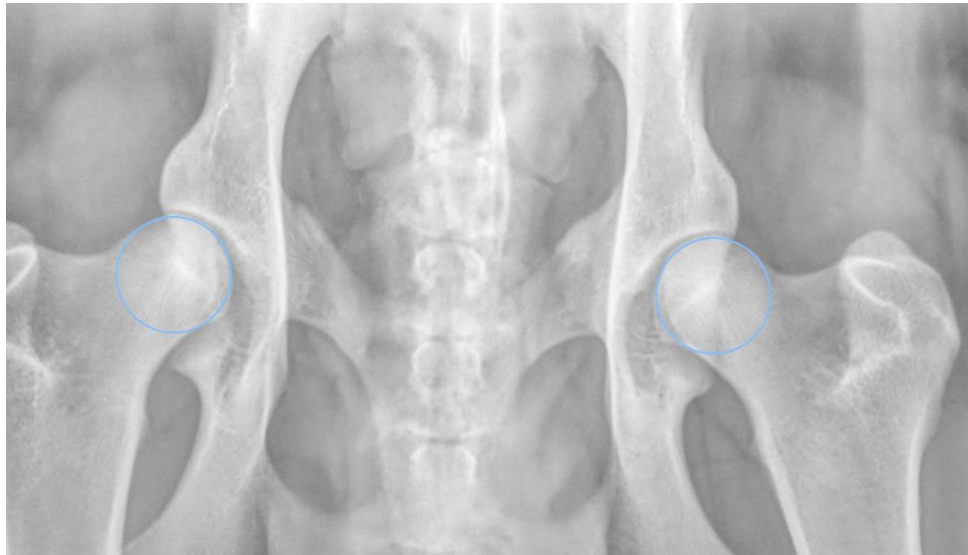
Dr. Claudia Giuliani,
DVM

INVOICE

54617

DATE

10-14-22



The information and recommendations provided are based on the images presented by the referring veterinarian/sonographer. No evaluation can be communicated regarding pathology that was not visible in the image/video clips provided.

Thank you for this referral. If the clinical or image interpretation does not parallel your findings or if I can be of any further assistance please contact me.

Nele Eley, DVM, Dr. med. vet., DipECVDI
European Specialist in Veterinary Diagnostic Imaging, Cert. Radiology,
Senior lecturer University of Giessen, Germany, Veterinary Faculty, Department of Radiology
Nele.Eley@sonopath.com