



**PATIENT**

Champ Craven

**PRESENTING CLINICAL SIGNS**

Developing congestive heart failure, as per the echocardiograph report (report is attached to this report). Is currently on furosemide (20mg, 1/4 tablet per day), Fortekor (2.5 mg, 0.5 tablet twice daily), Vetmedin (1.25mg, one capsule twice daily) and Spironolactone (25 mg, 1/4 tablet once daily)

**SPECIES**

Canine

**RADIOGRAPHIC STUDY OF THE THORAX**

Right/left lateral and dorsoventral views totaling 3 images available for review.

**BREED**

Chihuahua

**RADIOGRAPHIC FINDINGS**

Severe left sided cardiomegaly with a vertebral heart score of approximately 12.5 is seen. There is severe bulging of the left atrium. The trachea is elevated.

**SEX**

Neutered Male

Precarinal thoracic tracheal collapse is seen as well as splitting and compression of the left mainstem bronchus.

The sternal contact of the cardiac silhouette is increased.

**AGE**

13 Years

A moderate vascular lung pattern is seen. At this point, there is no evidence of cardiogenic pulmonary edema.

Moderate gastric aerophagia is noted.

**INTERPRETED BY**

Nele Eley, DVM  
Dr. med. Vet. DipECVDF

**RADIOGRAPHIC DIAGNOSIS**

- Severe left sided cardiomegaly with left atrial enlargement and presumed ongoing congestive heart failure.

**HOSPITAL NAME**

Truscott Animal  
Hospital

**INTERPRETATION OF THE FINDINGS & FURTHER RECOMMENDATIONS**

The lungs do not reveal edema at this point; however, dilation of the pulmonary veins appears to be present, and it has to be considered that the patient is under diuretic treatment which likely compensates the ongoing cardiac failure based on what constated from radiographs. There also is a mass effect of the severely enlarged left atrium onto the left mainstem bronchus. The aerophagia likely reflects the dyspneic state of the patient.

**REFERRING VET**

Medhat Meawad

**INVOICE**

47818

**DATE**

10-14-21



**PATIENT**

Champ Craven

**SPECIES**

Canine

**BREED**

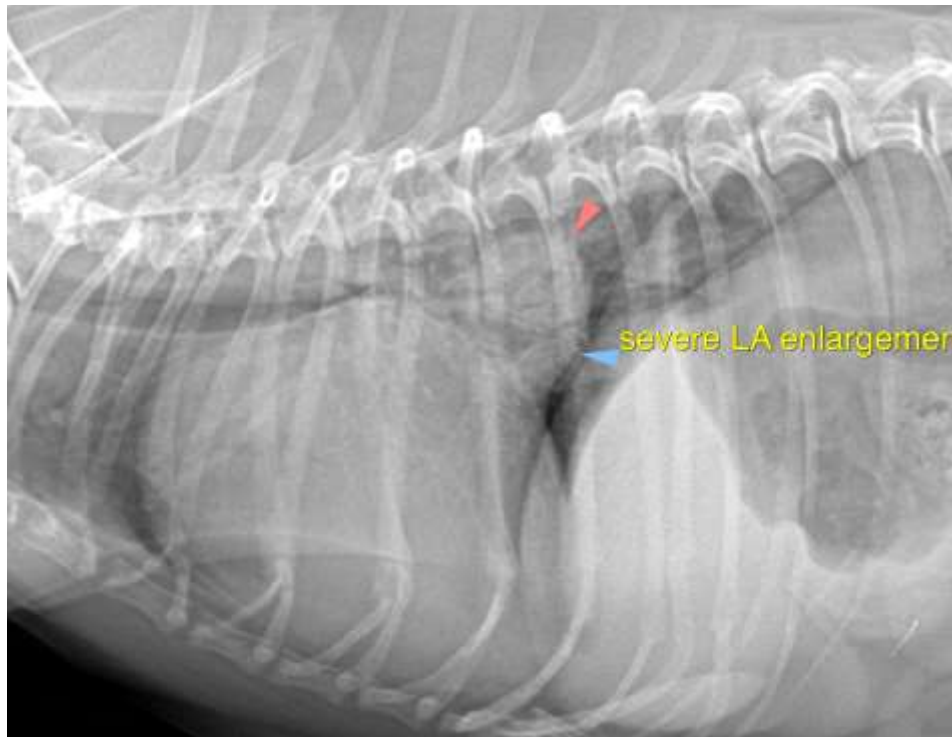
Chihuahua

**SEX**

Neutered Male

**AGE**

13 Years



**INTERPRETED BY**

Nele Eley, DVM  
Dr. med. Vet. DipECVDI

The information and recommendations provided are based on the images presented by the referring veterinarian. No evaluation can be communicated regarding pathology that was not visible in the image/video clips provided.

**HOSPITAL NAME**

Truscott Animal  
Hospital

Thank you for this referral. If the clinical or image interpretation does not parallel your findings or if I can be of any further assistance please contact me.

**Nele Eley**, DVM, Dr. med. vet., DipECVDI  
European Specialist in Veterinary Diagnostic Imaging, Cert. Radiology,  
Senior lecturer University of Giessen, Germany, Veterinary Faculty, Department of Radiology  
Nele.Eley@sonopath.com

**REFERRING VET**

Medhat Meawad

**INVOICE**

47818

**DATE**

10-14-21