


PATIENT PRESENTING CLINICAL SIGNS

Rosie Bunger Presented to ER 10/12 for right sided nasal and oral discharge and lethargy, clear in color. Owner notes heavy salivation from right side of the mouth. Acts as if she cannot open her jaw. Inappetence since Sunday. Not wanting to e/d. Paws at her food and water bowl as if she wants to eat and drink but can't. Is on Clindamycin and Carprofen, last dose was yesterday morning. Does go to dog parks, was there recently. No s/c/v/d. VF immy in hospital negative 10/12. Presented today 10/13 for dental CT and consult. CBC/Chemistry: WNL. No oral lesions, jaw palpates symmetrical, no abnormalities on oral exam.

SPECIES

Canine

BREED

 Cavalier King
 Charles Spaniel

COMPUTED TOMOGRAPHIC STUDY OF THE HEAD

Plain and post-contrast studies available for review.

COMPUTED TOMOGRAPHIC FINDINGS
SEX

Spayed Female

Marked leftward deviation of the nasal septum is seen within the mid third of the nasal cavities. There is mild bilaterally symmetric swelling of the mucosal lining of the turbinates and conchae. No evidence of turbinate destruction, soft tissue mass, or foreign material.

AGE

4 Years

There is no evidence of significant dental disease other than moderate widening of the periodontal space of the triadan #101. No evidence of a dental nasal fistula is seen.

The orbital tissues present within normal limits.

The patient has a brachycephalic head conformation with flat contour of the supraoccipital bone.

INTERPRETED BY

 Nele Eley (Ondreka),
 DVM Dr. med. vet.,
 DipECVDI

Moderate bilateral lateral ventriculomegaly is seen. No structural abnormality of the brain parenchyma is noted.

Both tympanic bullae are occupied with uniformly fluid attenuating contrast negative material. The osseous lining of the bullae presents within normal limits.

The regional lymph nodes present within normal limits.

HOSPITAL NAME

Scottsdale Vet Clinic

COMPUTED TOMOGRAPHIC DIAGNOSIS
REFERRING VET

Dr. Engelschall

- Mild bilaterally symmetric non-destructive rhinitis
- Moderate periodontitis triadan #101
- Bilateral otitis media – suspect primary secretory otitis media.
- Ventriculomegaly of the brain
- Brachycephaly and caudal occipital malformation

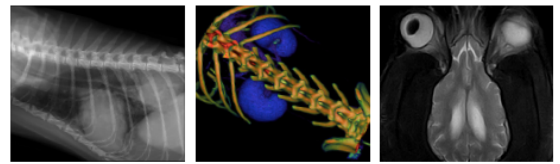
INTERPRETATION OF FINDINGS & FURTHER RECOMMENDATIONS
INVOICE

42108

DATE

10/13/22

The CT findings are compatible with non-destructive rhinitis. Inflammatory rhinitis such as allergic or irritant rhinitis is considered most likely. Lymphoplasmacytic rhinitis and infectious rhinitis such as viral or bacterial cannot be ruled out entirely as differential diagnoses. Further definition by means of rhinoscopy with sampling could be considered in case of persisting clinical signs. There is no evidence of fungal infection, neoplastic pathology, or foreign material, and no significant dental changes or dental nasal fistulae.



PATIENT The otitis media is likely to be primary secretory. Infectious otitis is unlikely but cannot be ruled out entirely.

Rosie Bunger

The ventriculomegaly of the brain is unlikely to be of clinical significance. Ventriculomegaly is a common subclinical finding unless accompanied by active distention of the ventricular system with increased intraventricular pressures.

SPECIES

Canine

BREED

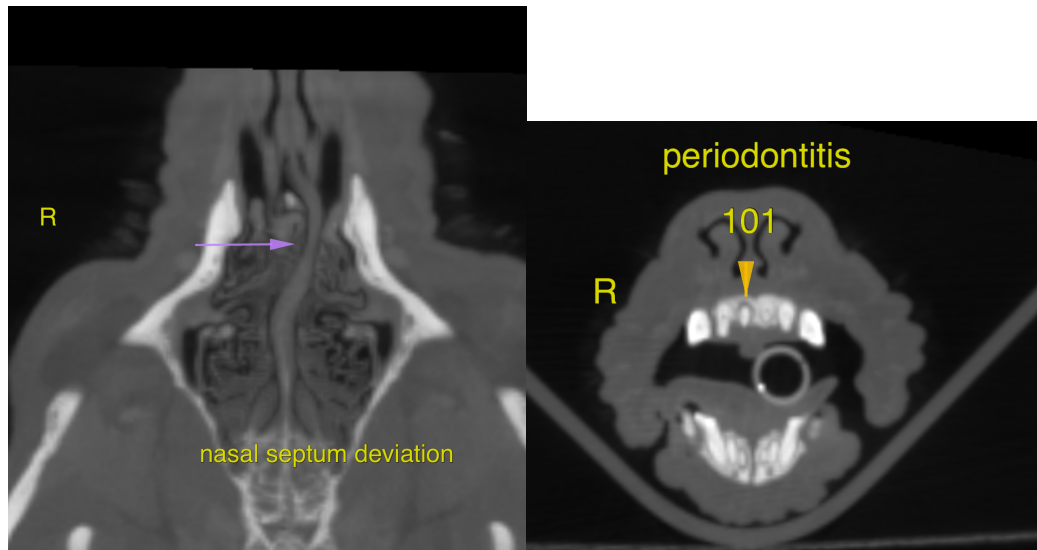
Cavalier King Charles Spaniel

SEX

Spayed Female

AGE

4 Years

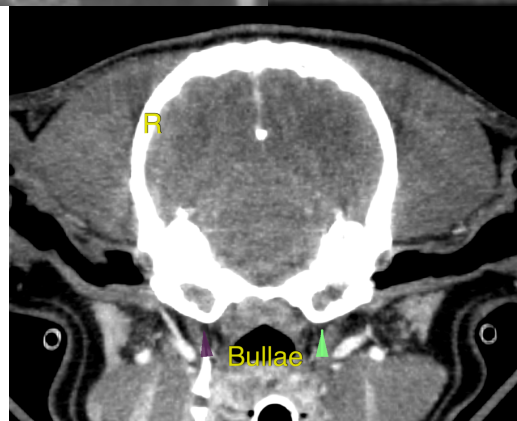


INTERPRETED BY

Nele Eley (Ondreka),
DVM Dr. med. vet.,
DipECVDI

HOSPITAL NAME

Scottsdale Vet Clinic



REFERRING VET

Dr. Engelschall

The information and recommendations provided are based on the images presented by the referring veterinarian. No evaluation can be communicated regarding pathology that was not visible in the image/video clips provided.

INVOICE

42108

DATE

10/13/22

Thank you for this referral. If the clinical or image interpretation does not parallel your findings or if I can be of any further assistance please contact me.

Nele Eley (Ondreka), DVM, Dr. med. vet., DipECVDI
European Specialist in Veterinary Diagnostic Imaging, Cert. Radiology,
Senior lecturer University of Giessen/Germany, Veterinary Faculty, Department of Radiology.
Nele.Eley@sonopath.com