

PATIENT PRESENTING CLINICAL SIGNS

Koda Toon 1-week progressive hyperthermia and lumbosacral pain. No clinical improvement with enrofloxacin and corticosteroids.

SPECIES COMPUTED TOMOGRAPHIC STUDY OF THE THORACOLUMBAR SPINE

Canine Plain and post-contrast studies in soft tissue and bone windows available for review.

COMPUTED TOMOGRAPHIC FINDINGS

BREED Number, alignment, and general anatomy of the thoracic and lumbar vertebrae present within normal limits.
Husky X

SEX

Neutered Male Mild dorsal bulging of the annulus fibrosis of the lumbosacral disc and mild dorsal bulging of the dorsal longitudinal ligament are seen at the lumbosacral junction. There is mild dorsal deviation of the dural tube. A thin rim of epidural fat is maintained ventral and dorsal to the cauda equina. Dorsal narrowing of the vertebral canal and/or step formation are not noted. Minimal dorsal bulging of the L6/7 disc and focal mineralization of the L5/6 intervertebral disc are seen. There is no evidence of aggressive bone lesions of the vertebral endplates.

AGE

2 Years The hip and epaxial musculature present within normal limits.
The regional lymph nodes within the hypogastrium present within normal limits as well.

COMPUTED TOMOGRAPHIC DIAGNOSIS

INTERPRETED BY

Nele Eley (Ondreka),
DVM Dr. med. vet.,
DipECVDI

- Mild lumbosacral stenosis due to mild intervertebral disc protrusion
- Minimal disc protrusion L6/7

INTERPRETATION OF FINDINGS & FURTHER RECOMMENDATIONS

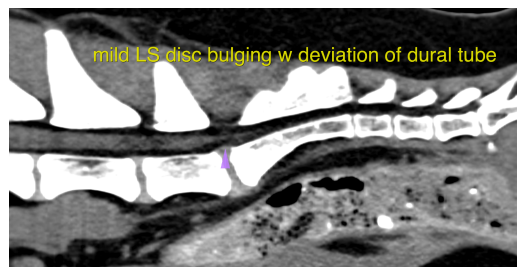
HOSPITAL NAME

Animal Health
Partners

The CT study reveals mild degenerative lumbosacral stenosis. Clinical significance is variable and uncertain. No signs of discospondylitis are noted. However, acute discospondylitis may not be evident since the imaging findings tend to lag behind the clinical course of the disease. CSF analysis could be considered in order to rule out other underlying causes of the patient's clinical signs, including meningitis and other.

REFERRING VET

Dr. Edouard Marchal



INVOICE

42110

DATE

10/13/22



PATIENT

The information and recommendations provided are based on the images presented by the referring veterinarian. No evaluation can be communicated regarding pathology that was not visible in the image/video clips provided.

Koda Toon

SPECIES

Thank you for this referral. If the clinical or image interpretation does not parallel your findings or if I can be of any further assistance please contact me.

Canine

BREED

Nele Eley (Ondreka), DVM, Dr. med. vet., DipECVDI
European Specialist in Veterinary Diagnostic Imaging, Cert. Radiology,
Senior lecturer University of Giessen/Germany, Veterinary Faculty, Department of Radiology.
Nele.Eley@sonopath.com

Husky X

SEX

Neutered Male

AGE

2 Years

INTERPRETED BY

Nele Eley (Ondreka),
DVM Dr. med. vet.,
DipECVDI

HOSPITAL NAME

Animal Health
Partners

REFERRING VET

Dr. Edouard Marchal

INVOICE

42110

DATE

10/13/22