

PATIENT PRESENTING CLINICAL SIGNS

Hazel Racine history of right lateral suture surgery four months ago owner mentioned that patient still limping on the right hind leg, patient finished the course of PT and laser therapy

SPECIES RADIOGRAPHIC STUDY OF THE THORAX & ABDOMEN

Canine Right lateral and ventrodorsal views of the thorax and abdomen each totaling 4 images available for review.

BREED RADIOGRAPHIC FINDINGS

Mini Poodle **Abdomen**

The surrounding bony structures are within normal limits.

SEX No abnormalities of the extraabdominal soft tissues are noted. The abdominal wall is smooth and thin.
MN

The serosal detail is maintained throughout the peritoneal and retroperitoneal space.

AGE The liver is appropriate in position, size and presents uniform opacity.

7 Years The splenic head is in the anticipated position and within normal limits for size and opacity. The splenic body and tail are considered normal for position, size, shape and opacity.

INTERPRETED BY The assessment of the right kidney is limited by superimposition with the gastrointestinal tract. Both kidneys are seen and present with normal size, shape, delineation and opacity. The urinary bladder is in its anticipated position. No radiopaque calculi are noted throughout the upper and lower urinary tract.
Nele Eley, DVM
Dr. med. Vet. DipECVDI

HOSPITAL NAME The stomach is in its anticipated position and presents normal content.

Animal Surgical Center The small intestinal loops are of even diameter and non-dilated, a small amount of gas is seen within the small intestinal loops and considered within normal limits.

The colon is seen in the expected position and presents with appropriate content.

REFERRING VET **Thorax**

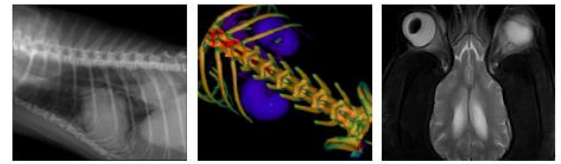
Garden City Park Animal Hospital Mild T3/4 spondylosis deformans is seen.

The extrathoracic soft tissues present homogeneous without abnormalities.

INVOICE The heart is of normal size and shape and there is no evidence of cardiac chamber enlargement, a vascular lung pattern, or congestive heart failure. The pulmonary vasculature is within normal limits. The vertebral heart score is 10.
54710

DATE The cranial mediastinum presents the expected soft tissue opacity. The mediastinal width is less than twice the width of the vertebral column at the same level.

10-13-22



PATIENT

Hazel Racine

Minimal dorsal flattening of the tracheal lumen is noted immediately cranial to the cranial thoracic aperture.

The bronchial tree presents with thin walls and tapers uniformly towards the periphery as expected.

SPECIES

Canine

The lung parenchyma presents the expected architecture and opacity. The intrapulmonary vascular branching is seen up to the third order lung vessels.

BREED

Mini Poodle

The diaphragm is well delineated with even surface and the expected mild cranial bulging of the diaphragmatic cupola.

RADIOGRAPHIC DIAGNOSIS

- Normal age related radiographic prestation of the abdomen and thorax with minimal dorsal flattening of the pre-thoracic trachea.

SEX

MN

INTERPRETATION OF THE FINDINGS & FURTHER RECOMMENDATIONS

The radiographic survey of thorax and abdomen reveals normal age related findings. The mild flattening of the pre-thoracic cervical trachea is likely to be a function of the head position. However, dynamic tracheal disease cannot be ruled out entirely. Clinical correlation is required.

AGE

7 Years

INTERPRETED BY

Nele Eley, DVM
Dr. med. Vet. DipECVDI

HOSPITAL NAME

Animal Surgical
Center

REFERRING VET

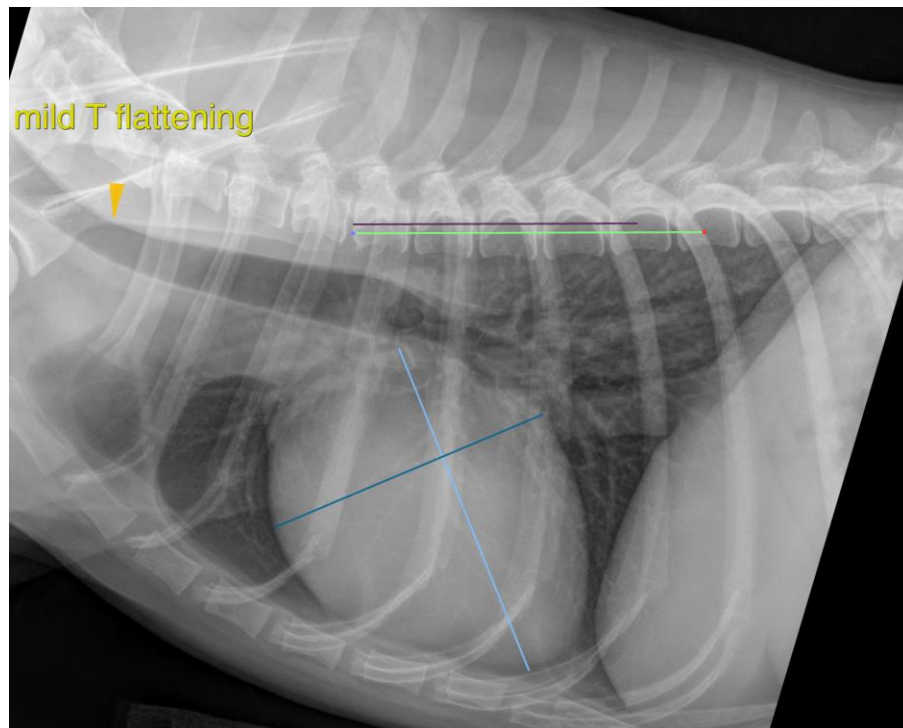
Garden City Park
Animal Hospital

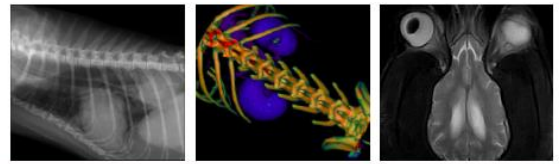
INVOICE

54710

DATE

10-13-22





PATIENT

Hazel Racine

The information and recommendations provided are based on the images presented by the referring veterinarian/sonographer. No evaluation can be communicated regarding pathology that was not visible in the image/video clips provided.

Thank you for this referral. If the clinical or image interpretation does not parallel your findings or if I can be of any further assistance please contact me.

SPECIES

Canine

Nele Eley, DVM, Dr. med. vet., DipECVDI
European Specialist in Veterinary Diagnostic Imaging, Cert. Radiology,
Senior lecturer University of Giessen, Germany, Veterinary Faculty, Department of Radiology
Nele.Eley@sonopath.com

BREED

Mini Poodle

SEX

MN

AGE

7 Years

INTERPRETED BY

Nele Eley, DVM
Dr. med. Vet. DipECVDI

HOSPITAL NAME

Animal Surgical
Center

REFERRING VET

Garden City Park
Animal Hospital

INVOICE

54710

DATE

10-13-22