

**PATIENT**Cindy Lou Who  
Carson**PRESENTING CLINICAL SIGNS**

Patient presented for bleeding rear toe that has been going on for a few weeks. Bleeding soft tissue mass present on distal P3 of left rear foot, blood work wnl, unintentional weight and some lethargy noticed by owner.

**SPECIES**

Feline

**RADIOGRAPHIC STUDY OF THE THORAX**

Right lateral and ventrodorsal views totaling 2 images available for review.

**BREED**

DSH

**RADIOGRAPHIC FINDINGS**

The degree of pulmonary inflation is moderate. A generalized bronchial lung pattern is noted. The right caudal lung lobe presents volume loss. An irregular shaped soft tissue mass is seen in the caudomedial aspect of the right caudal lung lobe. The right middle lobe presents compensatory over inflation. No evidence of additional pulmonary nodules is seen.

**SEX**

FS

Course and width of the trachea are considered within normal limits. There is no evidence of mediastinal widening.

The radiographic presentation of the cardiac silhouette is within normal limits.

**AGE**

9 Years, 11 Months

**RADIOGRAPHIC DIAGNOSIS**

- Single lung mass within the right caudal lung lobe.
- Bronchial lung pattern: age related versus underlying or low grade lower airway syndrome.

**INTERPRETED BY**Nele Eley, DVM  
Dr. med. Vet. DipECVDF**INTERPRETATION OF THE FINDINGS & FURTHER RECOMMENDATIONS**

The radiographic study reveals a large soft tissue opaque mass within the caudomedial aspect of the right caudal lung lobe. This may represent metastatic disease of another primary tumor however it is considered more likely that this represents a primary neoplasia of the lung such as bronchial carcinoma. Bronchial carcinoma is known to present with metastases in the digits which is called the lung-digit syndrome and a rather typical presentation of bronchial carcinoma especially in cats. Granuloma, abscess, hematoma are theoretical differential diagnoses for the pulmonary mass which, however, all are thought highly likely.

**HOSPITAL NAME**POCONO PEAK  
VETERINARY  
CENTER**REFERRING VET**

Dr. Christine Coyle

**INVOICE**

54638

**DATE**

10-13-22



**PATIENT**

Cindy Lou Who  
Carson

**SPECIES**

Feline

**BREED**

DSH

**SEX**

FS

**AGE**

9 Years, 11 Months

**INTERPRETED BY**

Nele Eley, DVM  
Dr. med. Vet. DipECVDI

**HOSPITAL NAME**

POCONO PEAK  
VETERINARY  
CENTER

**REFERRING VET**

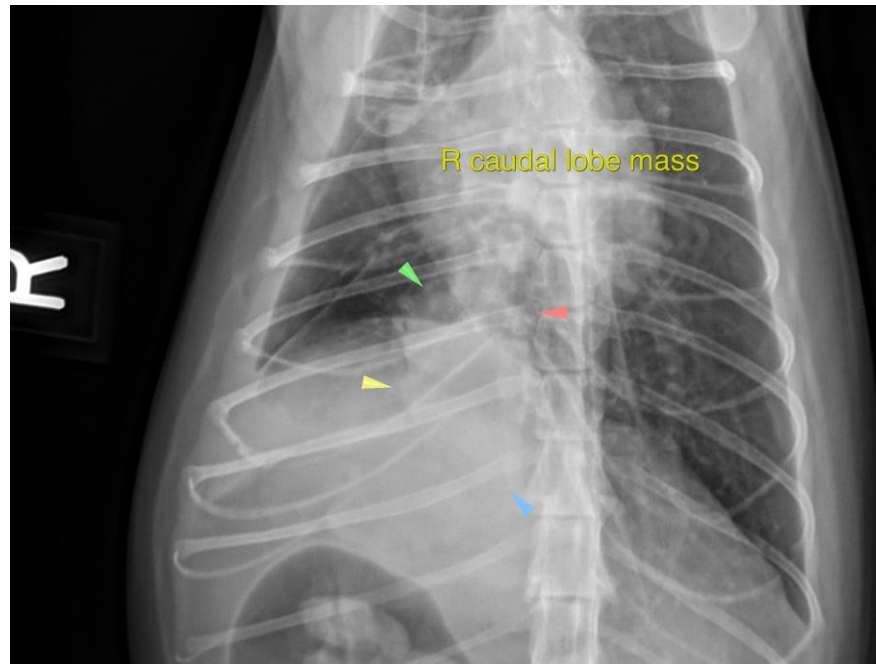
Dr. Christine Coyle

**INVOICE**

54638

**DATE**

10-13-22



The information and recommendations provided are based on the images presented by the referring veterinarian/sonographer. No evaluation can be communicated regarding pathology that was not visible in the image/video clips provided.

Thank you for this referral. If the clinical or image interpretation does not parallel your findings or if I can be of any further assistance please contact me.

**Nele Eley, DVM, Dr. med. vet., DipECVDI**  
European Specialist in Veterinary Diagnostic Imaging, Cert. Radiology,  
Senior lecturer University of Giessen, Germany, Veterinary Faculty, Department of Radiology  
Nele.Eley@sonopath.com