



PATIENT

Jojo Toman

PRESENTING CLINICAL SIGNS

Presented for acute onset of limping/lameness noted on RH after visiting the dog beach. Limping has been present for approx 10 days. Owner unsure if hips or knee injury.
Abnormal PE/Chem/CBC/UA Results: Toe touching while standing. Unable to elicit cranial drawer during sedated examination.

SPECIES

Canine

RADIOGRAPHIC STUDY OF THE STIFLES & PELVIS

Mediolateral views of both stifles and ventrodorsal hip extended view of the pelvis totaling 3 images available for review.

BREED

German Shepherd

RADIOGRAPHIC FINDINGS

Both stifles present within normal limits. There is no evidence of articular swelling, cranial thrust of the tibia, or osteophytosis. The subchondral bone surfaces are intact and smooth. No evidence of soft tissue swelling is seen in the long digital extensor origin.

SEX

FE

Both coxofemoral joints present within normal limits. No evidence of dysplasia, osteoarthritis, or traumatic osseous injury is seen.

AGE

11.8 Months

Mild to moderate patchy medullary sclerosis is noted in the diaphysis of all long bones accentuating the right femur.

The muscle volume of both hind limbs appears adequate and symmetric.

INTERPRETED BY

Nele Eley, DVM
Dr. med. Vet. DipECVDI

RADIOGRAPHIC DIAGNOSIS

- Panosteitis.
- Radiographically normal stifles and coxofemoral joints.

HOSPITAL NAME

Boca Park Animal Hospital

INTERPRETATION OF THE FINDINGS & FURTHER RECOMMENDATIONS

The radiographic study of the hind limbs reveals panosteitis eosinophilica which is a sterile juvenile form of osteomyelitis which is typically self-limiting and ceases with reaching skeletal maturity. The radiographic changes are most pronounced in the right hind limb at this point; however, this does not necessarily correlate with the clinical picture since the sclerosis may lag behind the clinical signs. Clinical correlation is required in order to determine whether the radiographic findings explain the clinical signs completely. Treatment of panosteitis is typically not necessary other than pain management with systemic NSAID administration and restriction of the daily caloric intake could be considered as well.

REFERRING VET

Ashman/Ensign

INVOICE

47794

DATE

10-13-21



PATIENT

Jojo Toman

SPECIES

Canine

BREED

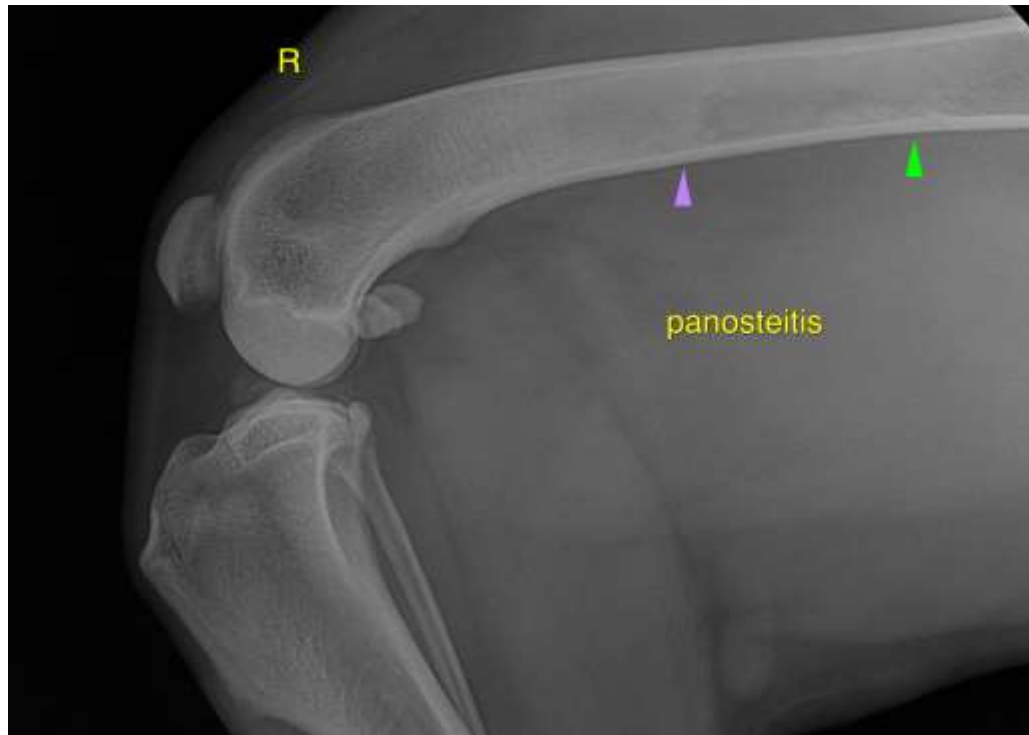
German Shepherd

SEX

FE

AGE

11.8 Months



INTERPRETED BY

Nele Eley, DVM
Dr. med. Vet. DipECVDI

The information and recommendations provided are based on the images presented by the referring veterinarian. No evaluation can be communicated regarding pathology that was not visible in the image/video clips provided.

HOSPITAL NAME

Boca Park Animal
Hospital

Thank you for this referral. If the clinical or image interpretation does not parallel your findings or if I can be of any further assistance please contact me.

Nele Eley, DVM, Dr. med. vet., DipECVDI
European Specialist in Veterinary Diagnostic Imaging, Cert. Radiology,
Senior lecturer University of Giessen, Germany, Veterinary Faculty, Department of Radiology
Nele.Eley@sonopath.com

REFERRING VET

Ashman/Ensign

INVOICE

47794

DATE

10-13-21