



PATIENT

Shasta Mortensen

PRESENTING CLINICAL SIGNS

Patient had a small mass on her upper left lip excised on 6/21/21. Diagnosis was: Sweat Gland Adenocarcinoma, low grade malignancy with complete excision. Mass on L neck appeared a couple months later and P was in on 8/11/21 for pre-surgical x-rays ABD/Thorax/Head & Neck. All WNL. Owner elected ultrasound of neck and abdomen to further evaluate. Abnormal PE/Chem/CBC/UA Results: WNL per rDVM

SPECIES

Feline

ULTRASONOGRAPHIC FINDINGS

BREED

DSH

Urinary System

The urinary bladder is moderately distended and contains a moderate amount of non-shadowing echogenic debris. The wall of the urinary bladder is uniform in thickness and layering.

SEX

FS

Both kidneys are symmetrical in size and shape and present with regular echoarchitecture. The corticomedullary ratio is within normal limits, the demarcation between cortex and medulla is mildly ill-defined. The renal cortices are hypoechoic compared with the spleen; multifocal small hyperechoic foci are present. The medullary segments are nearly anechoic. Minor echogenicity changes are seen within the medullary segments. The renal crest and pelvises present normal. The renal sinus is regular and hyperechoic. The renal diverticuli and ureters are not seen. The left kidney measures 3.5 cm in length and the right kidney measures 3.9 cm in length.

AGE

9/1/2008

Adrenal Glands

INTERPRETED BY

Nele Eley, DVM
Dr. med. Vet. DipECVDI

Both adrenal glands are recognized and regular in size, shape and echoarchitecture. Volume and size relationships between the cranial and caudal poles present normal respectively. The definition between the hypoechoic adrenal cortex and hyperechoic medulla is visible. The echogenicity of the parenchyma is largely uniform. The phrenicoabdominal veins can be traced passing the isthmus of the adrenal glands in the near field. The vascular routes of the phrenicoabdominal vessels and caudal vena cava are unimpeded. The adrenal glands measure less than 0.35 cm in diameter for both the cranial and caudal pole of the left and right adrenal gland.

HOSPITAL NAME

Rivers Edge Pet
Medical Center

Liver

Liver size appears to be normal subjectively taking body conformation, stomach position and the pointed extensions of the liver lobes into account. The hepatic parenchyma is uniformly hypoechoic and presents a coarse echotexture. The parenchymal echogenicity is iso- to hypoechoic relating to the fat within the falciform ligament and splenic parenchyma. The hepatic veins appear to be normal in diameter. The portal veins present with thin hyperechoic markings. The intrahepatic biliary tree is not seen. The extrahepatic biliary ducts are not seen. The gallbladder and cystic duct are thin walled and normal in size and shape. The gallbladder content is mainly anechoic. The common bile duct is seen between the proximal Duodenum and portal vein and is within normal limits. The fat within the portal hilus is regular in echotexture and hypoechoic.

REFERRING VET

Dr. Fulton

INVOICE

47778

Spleen

DATE

10-12-21



PATIENT

Shasta Mortensen

The spleen is elongated in long axis and triangular on cross section. The splenic parenchyma is homogenous and of a fine echotexture. The splenic capsule is thin, linear, and hyperechoic. Regular splenic vein branches are seen entering the hilus.

Gastrointestinal

SPECIES

Feline

The stomach and the intestines are visualized in their anticipated position. The rate of peristalsis appears to be normal. Gastrointestinal wall thicknesses are within the normal range. Wall layering appears to be preserved entirely throughout the visualized parts of the gastrointestinal tract. The luminal contents are regular. There is no sign of segmental or generalized dilation or stasis noted. The mesenteric fat is hypoechoic and regular in echotexture.

BREED

DSH

Pancreas

SEX

FS

Right and left lobes and body of the pancreas present with regular shape, echogenicity, and echotexture. The pancreas is thin, homogenous, slightly hyperechoic compared with the caudate liver lobe and nearly isoechoic to the surrounding mesenteric fat. The pancreaticoduodenal vein is seen in the right lobe. The pancreatic duct diameter is within normal limits.

Neck

AGE

9/1/2008

Both lobes of the thyroid gland are seen and present within normal limits.

One of the right parathyroids presents mild generalized enlargement and measures 2.5mm in diameter.

INTERPRETED BY

Nele Eley, DVM
Dr. med. Vet. DipECVDI

The "mass" in the left ventral neck represents the left mandibular salivary gland. It is well delineated with a crisp, thin hyperechoic capsule and leaf shaped measuring 1.6 cm in length and 1.0 cm in diameter. Mild internal heterogeneity is seen with maintained echoarchitecture but mild regional increase in echogenicity. Color Doppler confirms presence of internal vascularity accentuating the regular septations of the gland. No evidence of peripheral inflammation is seen.

HOSPITAL NAME

Rivers Edge Pet
Medical Center

The left medial retropharyngeal lymph node is seen deep and caudal of the mandibular salivary gland and presents within normal limits.

The digastricus muscle is seen rostral and deep to the mandibular salivary gland and presents within normal limits.

REFERRING VET

Dr. Fulton

ULTRASONOGRAPHIC DIAGNOSIS

- Normal age related abdomen.
- Urinary bladder debris.
- "Mass" in the left ventral neck presumed to represent the left mandibular salivary gland.
- Mild enlargement of one of the left parathyroid glands.

INVOICE

47778

INTERPRETATION OF THE FINDINGS & FURTHER RECOMMENDATIONS

DATE

10-12-21

The "mass" in the left ventral neck is in the anatomic position of the mandibular salivary gland superficial and caudal of the digastricus muscle, to the left of the base of the tongue and rostral margin of the larynx, and superficial and cranial of the medial retropharyngeal lymph node. The gland may be slightly increased in size and mildly increased in heterogeneity; however, a



PATIENT

comparison to the right mandibular salivary gland is not available.

Shasta Mortensen

I cannot delineate another mass or abnormal structure in the soft tissues of the left ventral neck.

SPECIES

One of the left parathyroid glands is slightly increased in size. Differential diagnosis includes primary and secondary hyperplasia, adenoma, and anatomic variant. Correlate with the laboratory values in order to determine the significance of this vary subtle increase in size.

Feline

The echogenic material within the urinary bladder may be crystals, proteinaceous material, cellular debris or fat droplets.

BREED

DSH

SEX

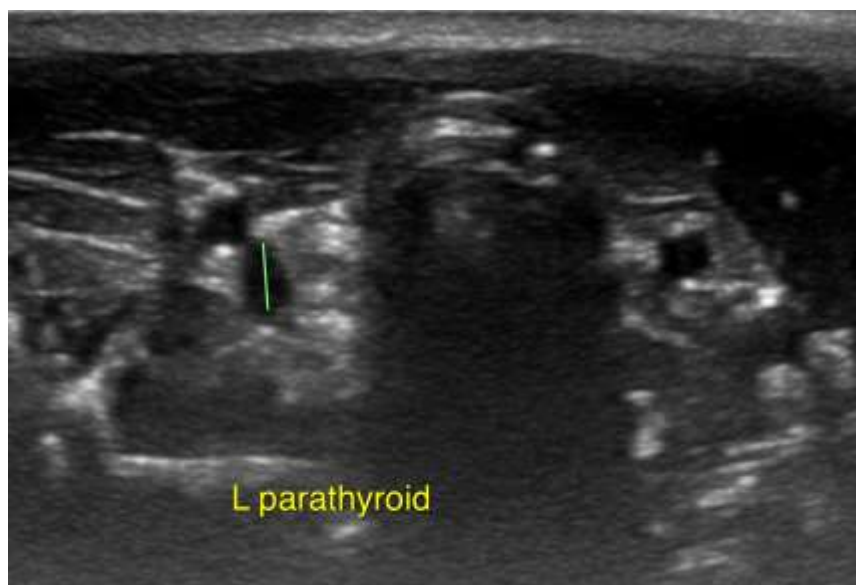
FS

AGE

9/1/2008

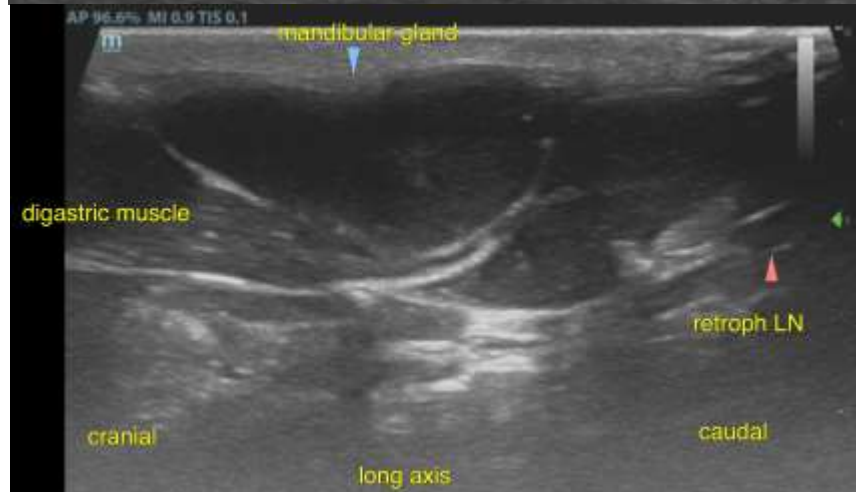INTERPRETED BY

Nele Eley, DVM
Dr. med. Vet. DipECVDI



HOSPITAL NAME

Rivers Edge Pet
Medical Center



REFERRING VET

Dr. Fulton

INVOICE

47778

DATE

10-12-21



PATIENT

Shasta Mortensen

The information and recommendations provided are based on the images presented by the referring veterinarian. No evaluation can be communicated regarding pathology that was not visible in the image/video clips provided.

Thank you for this referral. If the clinical or image interpretation does not parallel your findings or if I can be of any further assistance please contact me.

SPECIES

Feline

Nele Eley, DVM, Dr. med. vet., DipECVDI
European Specialist in Veterinary Diagnostic Imaging, Cert. Radiology,
Senior lecturer University of Giessen, Germany, Veterinary Faculty, Department of Radiology
Nele.Eley@sonopath.com

BREED

DSH

SEX

FS

AGE

9/1/2008

INTERPRETED BY

Nele Eley, DVM
Dr. med. Vet. DipECVDI

HOSPITAL NAME

Rivers Edge Pet
Medical Center

REFERRING VET

Dr. Fulton

INVOICE

47778

DATE

10-12-21