



**PATIENT**

Georgia Peach Lemon

**PRESENTING CLINICAL SIGNS**

Fell down stairs and came up limping on the left. Did not bear weight for an hour or so.  
Abnormal PE/Chem/CBC/UA Results: NA

**SPECIES**

Canine

**RADIOGRAPHIC STUDY OF THE STIFLES**

Mediolateral views of both stifles and ventrodorsal view of the pelvis with oblique view of the stifles totaling 3 images available for review.

**BREED**

French Bulldog

Stifle read requested.

**RADIOGRAPHIC FINDINGS**

The muscle volume of both hind limbs appears adequate and symmetric.

**SEX**

FS

No evidence of articular swelling of the stifle joints is seen. The patellae appear to be in situ. As far as assessable, there is no evidence of cranial thrust of the tibia and no significant osteoarthritic changes are noted.

**AGE**

3 Years

**RADIOGRAPHIC DIAGNOSIS**

- Radiographically normal stifle joints.

**INTERPRETED BY**

Nele Eley, DVM  
Dr. med. Vet. DipECVDI

**INTERPRETATION OF THE FINDINGS & FURTHER RECOMMENDATIONS**

There is no radiographic evidence of osseous or articular injury in the left and right stifle. Soft tissue trauma, inflammation, or degeneration cannot be ruled out entirely. Depending on the clinical presentation, spinal / neurological disease and workup could be considered as well.

**HOSPITAL NAME**

Pinebrook Animal  
Hospital

**REFERRING VET**

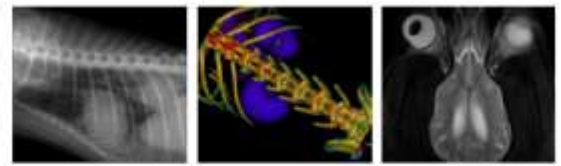
Dr. Britt Dubil

**INVOICE**

47763

**DATE**

10-11-21



**PATIENT**

Georgia Peach Lemon

The information and recommendations provided are based on the images presented by the referring veterinarian. No evaluation can be communicated regarding pathology that was not visible in the image/video clips provided.

**SPECIES**

Canine

Thank you for this referral. If the clinical or image interpretation does not parallel your findings or if I can be of any further assistance please contact me.

**BREED**

French Bulldog

**Nele Eley**, DVM, Dr. med. vet., DipECVDI  
European Specialist in Veterinary Diagnostic Imaging, Cert. Radiology,  
Senior lecturer University of Giessen, Germany, Veterinary Faculty, Department of Radiology  
Nele.Eley@sonopath.com

**SEX**

FS

**AGE**

3 Years

**INTERPRETED BY**

Nele Eley, DVM  
Dr. med. Vet. DipECVDI

**HOSPITAL NAME**

Pinebrook Animal  
Hospital

**REFERRING VET**

Dr. Britt Dubil

**INVOICE**

47763

**DATE**

10-11-21