



PATIENT

Bella Mitchell

PRESENTING CLINICAL SIGNS

Coughing x 2 days. Loud, honking, productive cough. Initially was bringing up visible phlegm, now it just ends with a retch and a swallow. Keeping her awake at night. Had the same thing happen last November.

SPECIES

Canine

Abnormal PE/Chem/CBC/UA Results: BAR. Unable to induce coughing with tracheal palpation. No abnormalities on thoracic auscultation.

BREED

Chihuahua

RADIOGRAPHIC STUDY OF THE THORAX

Right/left lateral and ventrodorsal views of the thorax totaling 3 images available for review.

RADIOGRAPHIC FINDINGS

Note redundancy of the dorsal tracheal ligament in the mid and caudal cervical trachea.

SEX

FS

A moderate generalized bronchial lung pattern is seen with bronchial wall mineralization and mild peribronchial cuffing. Occasional peripheral cylindrical bronchiectasis is seen. There are multiple pulmonary osteomas.

AGE

11 Years

No actual tracheal or bronchial collapse is noted.

The cardiovascular structures present within normal limits. The vertebral heart score is 9.1.

There is no evidence of mediastinal widening/mediastinal lymphadenomegaly.

INTERPRETED BY

Nele Eley, DVM
Dr. med. Vet. DipECVDI

RADIOGRAPHIC DIAGNOSIS

- Chronic bronchial lung pattern.
- Redundant dorsal tracheal ligament.

HOSPITAL NAME

Northshore
Veterinary Hospital

INTERPRETATION OF THE FINDINGS & FURTHER RECOMMENDATIONS

The radiographic findings support the presence of chronic lower airway disease such as irritant bronchitis, eosinophilic / allergic bronchopneumopathy, or infectious bronchitis including viral, bacterial, or parasitic. Further definition by means of airway endoscopy with airway sampling could be considered and would also allow for further assessment of the significance of the redundant dorsal tracheal ligament. No actual collapse is seen, and redundancy of the dorsal tracheal ligament can be an incidental finding. However, it can be associated with degenerative bronchomalacia and dynamic tracheal disease especially in elderly patients.

REFERRING VET

Kristin Williams

INVOICE

54396

DATE

10-1-22



PATIENT

Bella Mitchell

SPECIES

Canine

BREED

Chihuahua

SEX

FS

AGE

11 Years

INTERPRETED BY

Nele Eley, DVM
Dr. med. Vet. DipECVDI

HOSPITAL NAME

Northshore
Veterinary Hospital

REFERRING VET

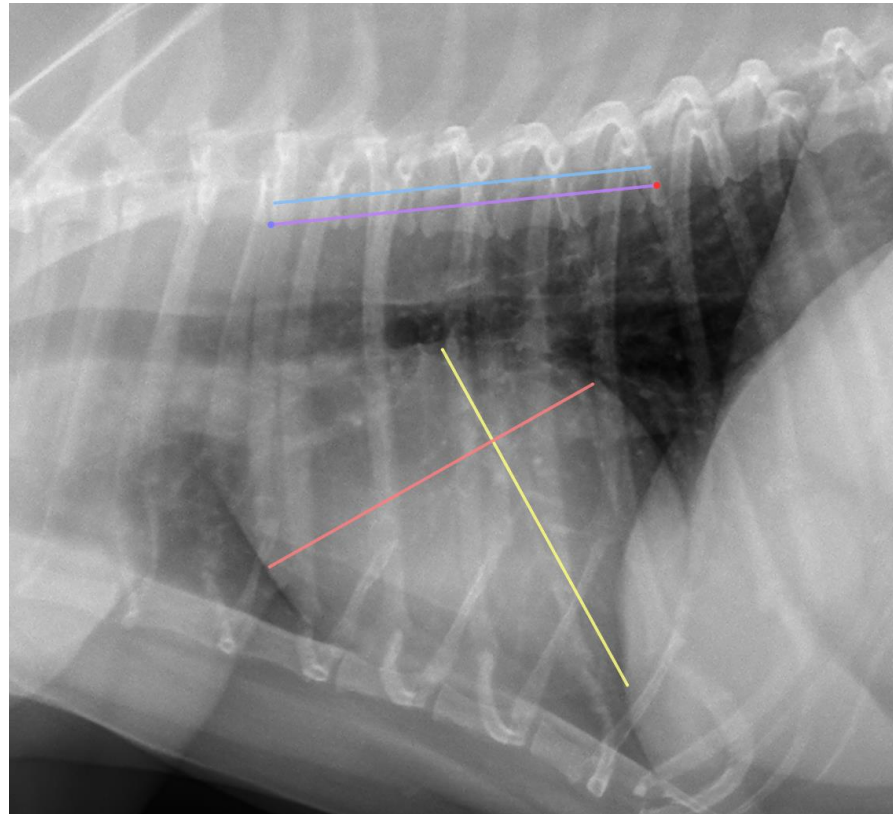
Kristin Williams

INVOICE

54396

DATE

10-1-22



The information and recommendations provided are based on the images presented by the referring veterinarian/sonographer. No evaluation can be communicated regarding pathology that was not visible in the image/video clips provided.

Thank you for this referral. If the clinical or image interpretation does not parallel your findings or if I can be of any further assistance please contact me.

Nele Eley, DVM, Dr. med. vet., DipECVDI
European Specialist in Veterinary Diagnostic Imaging, Cert. Radiology,
Senior lecturer University of Giessen, Germany, Veterinary Faculty, Department of Radiology
Nele.Eley@sonopath.com