


PATIENT PRESENTING CLINICAL SIGNS

Simao Antonio Previously diagnosed lipoma on the lateral aspect of the left shoulder region - changed in size and now has firm center. Suspected soft tissue sarcoma. Thoracic CT to evaluate for lung nodules and mass evaluation.

SPECIES COMPUTED TOMOGRAPHIC STUDY OF THE THORAX & FRONT LIMB

Canine Plain and post-contrast studies in soft tissue and lung windows available for review.

COMPUTED TOMOGRAPHIC FINDINGS
BREED

Cocker Spaniel

An 8.0 cm x 10 cm sized, fat attenuating mass is seen cranial and lateral of the left scapula. The fatty mass reveals soft tissue components within its center, represented by two approximately 2.5 cm sized soft tissue attenuating nodules with heterogeneous contrast enhancement, central cavitation and peripheral fat stranding, which are connected with each other by a soft tissue attenuating, ill-defined bridge. The fatty periphery of the mass is well delineated to the surrounding soft tissues and pushes the scapula and overlying muscles medially. Smaller condensed, soft tissue attenuating areas are distributed throughout the fatty mass and tortuous tumor feeding vessels are seen. A small soft tissue attenuating nodule of 3.0 mm diameter is seen medial of the fatty mass in the dorsum of the cervical spine.

SEX

Neutered Male

AGE

9 Years

There is no evidence of interstitial nodules on the lung. Multiple pulmonary osteomas are seen. A 5.0 mm sized bulla is seen embedded into the parenchyma of the right caudal lung lobe.

One sternal lymph node is mildly enlarged and rounded.

INTERPRETED BY

Nele Eley (Ondreka),
 DVM Dr. med. vet.,
 DipECVDI

The cardiovascular structures including the pulmonary vasculature are within normal limits.

Small incidental gas pockets are seen within the esophageal lumen, there is no evidence of abnormal dilation.

COMPUTED TOMOGRAPHIC DIAGNOSIS
HOSPITAL NAME

Animal Health
 Partners

- Fatty mass with two large and multiple small heterogeneously enhancing, soft tissue attenuating nodules lateral of the left scapula
- Small subcutaneous nodule medial of the fatty mass in the dorsum
- Pulmonary bulla
- Mild sternal lymphadenomegaly

REFERRING VET

Dr. Debbie Reynolds

INTERPRETATION OF FINDINGS & FURTHER RECOMMENDATIONS

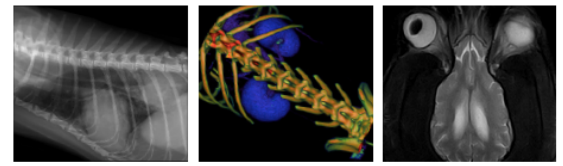
The periphery of the mass lateral of the left shoulder present very similar to lipoma. However, ill-defined, cavitating nodules are seen throughout the mass, and there is peripheral fat stranding noted as well as tortuous tumor feeding vessels. Liposarcoma or other soft tissue sarcoma is thought very likely based on the CT findings. Necrotizing or infarcted lipoma cannot be ruled out entirely, but is unfortunately thought unlikely here. The delineation of the mass is unclear, especially in its caudal aspect, and it also remains somewhat unclear whether the soft tissue attenuating subcutaneous nodule medial of the mass is part of this mass or represents a separate entity. Differential diagnoses for the enlarged sternal lymph nodes include reactive hyperplasia as well as early metastatic disease. Consider ultrasound guided fine needle aspiration for further definition.

INVOICE

26050

DATE

10/1/21



PATIENT

Simao Antonio

SPECIES

Canine

BREED

Cocker Spaniel

SEX

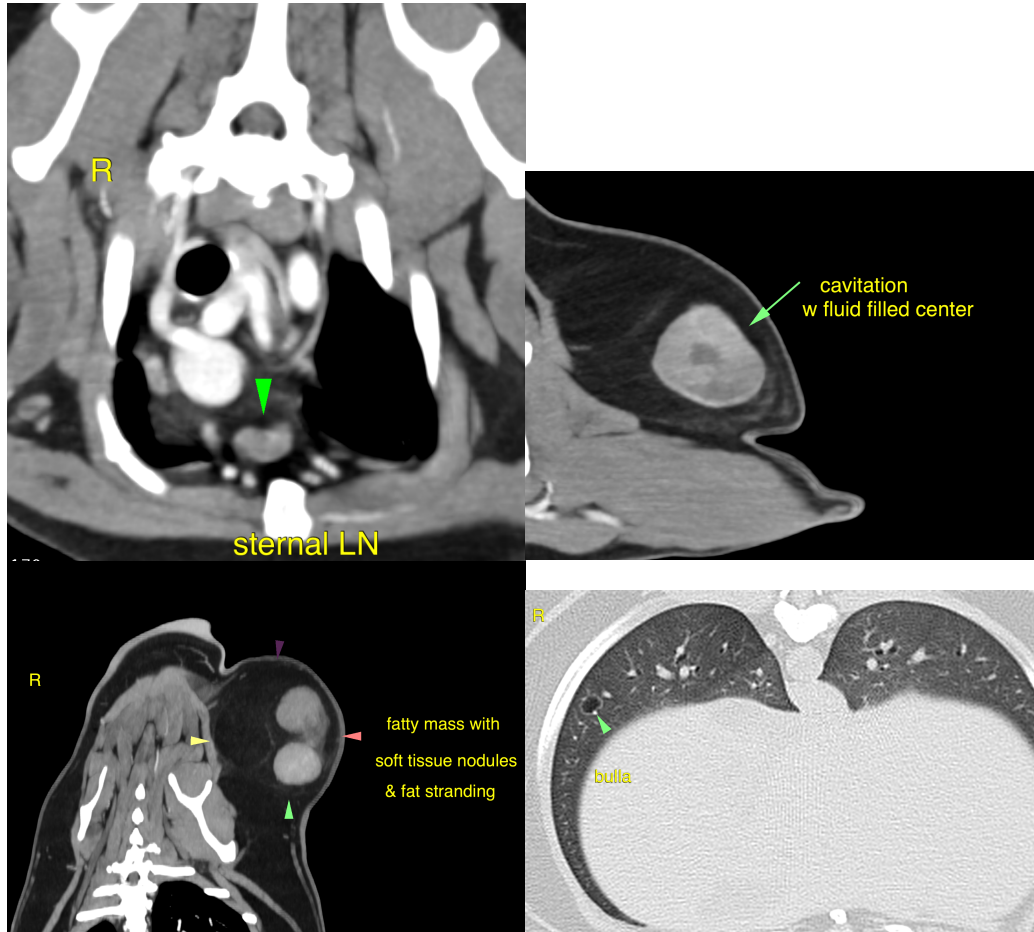
Neutered Male

AGE

9 Years

INTERPRETED BY

Nele Eley (Ondreka),
DVM Dr. med. vet.,
DipECVDI



HOSPITAL NAME

Animal Health Partners

The information and recommendations provided are based on the images presented by the referring veterinarian. No evaluation can be communicated regarding pathology that was not visible in the image/video clips provided.

Thank you for this referral. If the clinical or image interpretation does not parallel your findings or if I can be of any further assistance please contact me.

REFERRING VET

Dr. Debbie Reynolds

Nele Eley (Ondreka), DVM, Dr. med. vet., DipECVDI
European Specialist in Veterinary Diagnostic Imaging, Cert. Radiology,
Senior lecturer University of Giessen/Germany, Veterinary Faculty, Department of Radiology.
Nele.Eley@sonopath.com

INVOICE

26050

DATE

10/1/21