


PATIENT PRESENTING CLINICAL SIGNS

Lexi Evener P is here to check if is pregnant
 Abnormal PE/Chem/CBC/UA Results: advise o that she is 50 days and may be due in about 10 days
 we won't do vaccines since she is pregnant, advise o on pregnancy care

SPECIES RADIOGRAPHIC STUDY OF THE THORAX & ABDOMEN

Canine Lateral and ventrodorsal views of the abdomen and lateral whole body view provided for review.

BREED RADIOGRAPHIC FINDINGS

Shih Tzu X The mammae are prominent. The abdominal cavity is distended. Uterine enlargement is seen. There are 3 fetuses visible. No radiographic signs of complications noted.

SEX Mild gastric aerophagia is present.

Female The heart is of normal size and shape and there is no evidence of cardiac chamber or vascular enlargement. The pulmonary vasculature is within normal limits.

AGE The cranial mediastinum presents the expected soft tissue opacity. The mediastinal width is less than twice the width of the vertebral column at the same level.

7 Years The trachea is normal in diameter and presents the anticipated course. The luminal outline of the trachea is smooth.

INTERPRETED BY The bronchial tree presents with thin walls and tapers uniformly towards the periphery as expected.

Nele Eley (Ondreka), DVM Dr. med. vet., DipECVDI The lung parenchyma presents the expected architecture and opacity. The intrapulmonary vascular branching is seen up to the third order lung vessels.

The diaphragm is well delineated with even surface and the expected mild cranial bulging of the diaphragmatic cupola.

HOSPITAL NAME RADIOGRAPHIC DIAGNOSIS

- Animal Paradise Hospital
- Radiographically intact, late pregnancy with at least 3 fetuses
 - Radiographically normal thorax

REFERRING VET INTERPRETATION OF FINDINGS & FURTHER RECOMMENDATIONS

Dr. Kristen Hellwarth The radiographic findings are compatible with the history and age of the pregnancy. No signs of complication are noted radiographically. The thoracic structures present within normal limits.

INVOICE

26047

DATE

10/1/21



PATIENT

Lexi Evener

SPECIES

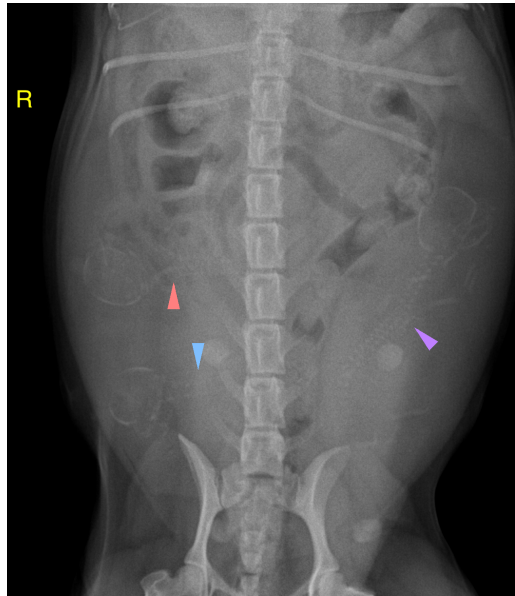
Canine

BREED

Shih Tzu X

SEX

Female



AGE

7 Years

The information and recommendations provided are based on the images presented by the referring veterinarian. No evaluation can be communicated regarding pathology that was not visible in the image/video clips provided.

Thank you for this referral. If the clinical or image interpretation does not parallel your findings or if I can be of any further assistance please contact me.

INTERPRETED BY

Nele Eley (Ondreka),
DVM Dr. med. vet.,
DipECVDI

Nele Eley (Ondreka), DVM, Dr. med. vet., DipECVDI
European Specialist in Veterinary Diagnostic Imaging, Cert. Radiology,
Senior lecturer University of Giessen/Germany, Veterinary Faculty, Department of Radiology.
Nele.Eley@sonopath.com

HOSPITAL NAME

Animal Paradise
Hospital

REFERRING VET

Dr. Kristen Hellwarth

INVOICE

26047

DATE

10/1/21