



PATIENT

Benjamin Jaasko

PRESENTING CLINICAL SIGNS

Presented for annual PE, vax, dental eval. Hx of adverse anesthesia event when neutered, was told no GA due to heart dz and risk of complications. O reports pt due for vax, but no records available today. Currently fed wet food only, but pt eats some puppy kibble. Lives with 1 other dog. Pt remains very active, no coughing, syncope, dyspnea or cyanosis reported. E/d/u/d wnl, no v/d/c/s. No hx of travel outside PNW. No other health concerns reported.

SPECIES

K9

Abnormal PE/Chem/CBC/UA Results: Grade II/VI left basilar systolic murmur; synchronous femoral pulses; chronic dental dz, stage 3-4/4

BREED

Terrier Mix

RADIOGRAPHIC STUDY OF THE THORAX

Right/left lateral and ventrodorsal views totaling 3 images available for review.

RADIOGRAPHIC FINDINGS

SEX

The surrounding bony structures are within normal limits.

MN

Mineralization and mild soft tissue mass effect are seen in the soft tissue of the ventral neck and partially superimposed onto the trachea level with the 3rd cervical vertebra.

AGE

9 Years

The heart is of normal size and shape and there is no evidence of cardiac chamber or vascular enlargement. The vertebral heart score is 9.2. The pulmonary vasculature is within normal limits.

INTERPRETED BY

Nele Eley, DVM
Dr. med. Vet. DipECVDI

The cranial mediastinum presents the expected soft tissue opacity. The mediastinal width is less than twice the width of the vertebral column at the same level.

The trachea is normal in diameter and presents the anticipated course. The luminal outline of the trachea is smooth.

HOSPITAL NAME

Reid Veterinary
Hospital

The bronchial tree presents with thin walls and tapers uniformly towards the periphery as expected.

The lung parenchyma presents the expected architecture and opacity. The intrapulmonary vascular branching is seen up to the third order lung vessels.

REFERRING VET

Jeff Popowich

The diaphragm is well delineated with even surface and the expected mild cranial bulging of the diaphragmatic cupola.

RADIOGRAPHIC DIAGNOSIS

- Normal age related thorax.
- No radiographic evidence of cardiomegaly or congestive heart failure.
- Potential for mineralizing mass in the ventral neck area.

INVOICE

47636

INTERPRETATION OF THE FINDINGS & FURTHER RECOMMENDATIONS

DATE

10-1-21

The radiographic examination of the cardiovascular and bronchopulmonary structures is within age related normal limits. Radiographically occult cardiac disease could be ruled out by means of a cardiac echo; however, at this point, there is no evidence of hemodynamic consequences in terms of dilation of the pulmonary vessels, caudal vena cava, or cardiogenic pulmonary edema.



PATIENT

Benjamin Jaasko

The mineralizing area with mild mass effect in the ventral neck varies slightly in position between the two lateral views and is not seen in the orthogonal view. Artifact cannot be ruled out; however, the possibility of a mineralizing soft tissue mass of thyroidal or other origin should be considered. Consider thorough clinical palpation of the area as well as ultrasound of the neck.

SPECIES

K9

BREED

Terrier Mix

SEX

MN

AGE

9 Years

INTERPRETED BY

Nele Eley, DVM
Dr. med. Vet. DipECVDI

HOSPITAL NAME

Reid Veterinary
Hospital

REFERRING VET

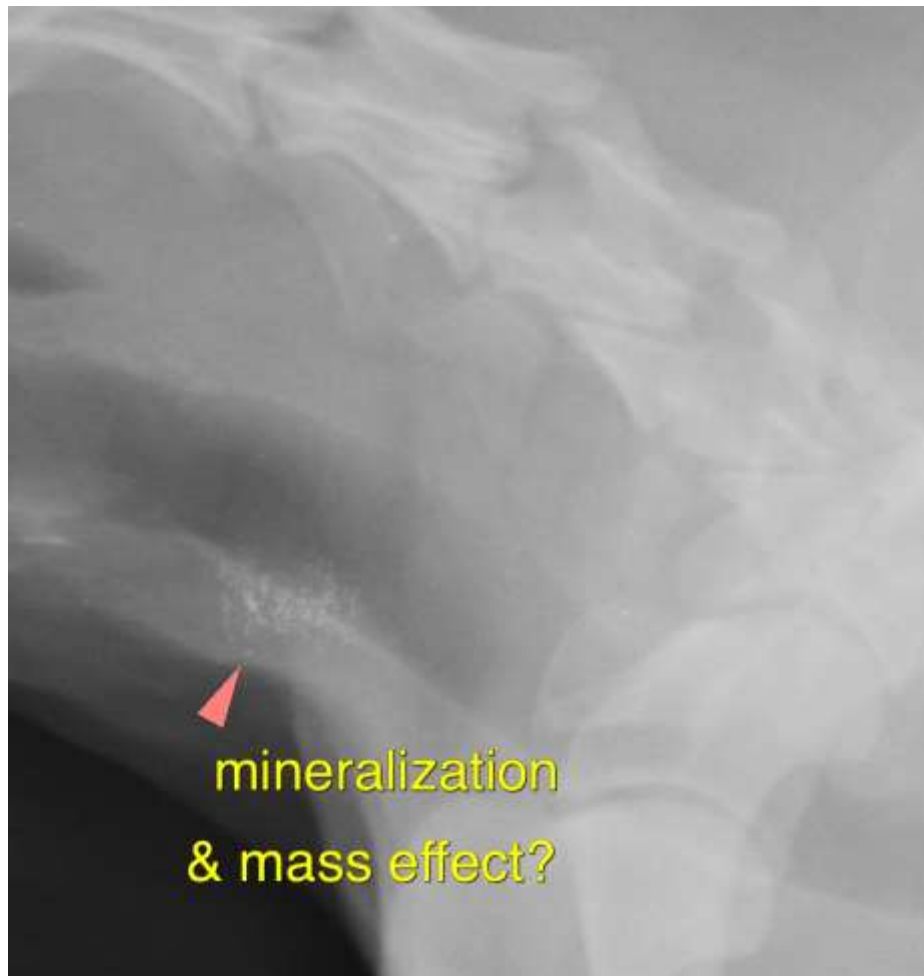Jeff Popowich

INVOICE

47636

DATE

10-1-21





PATIENT

Benjamin Jaasko

SPECIES

K9

BREED

Terrier Mix

SEX

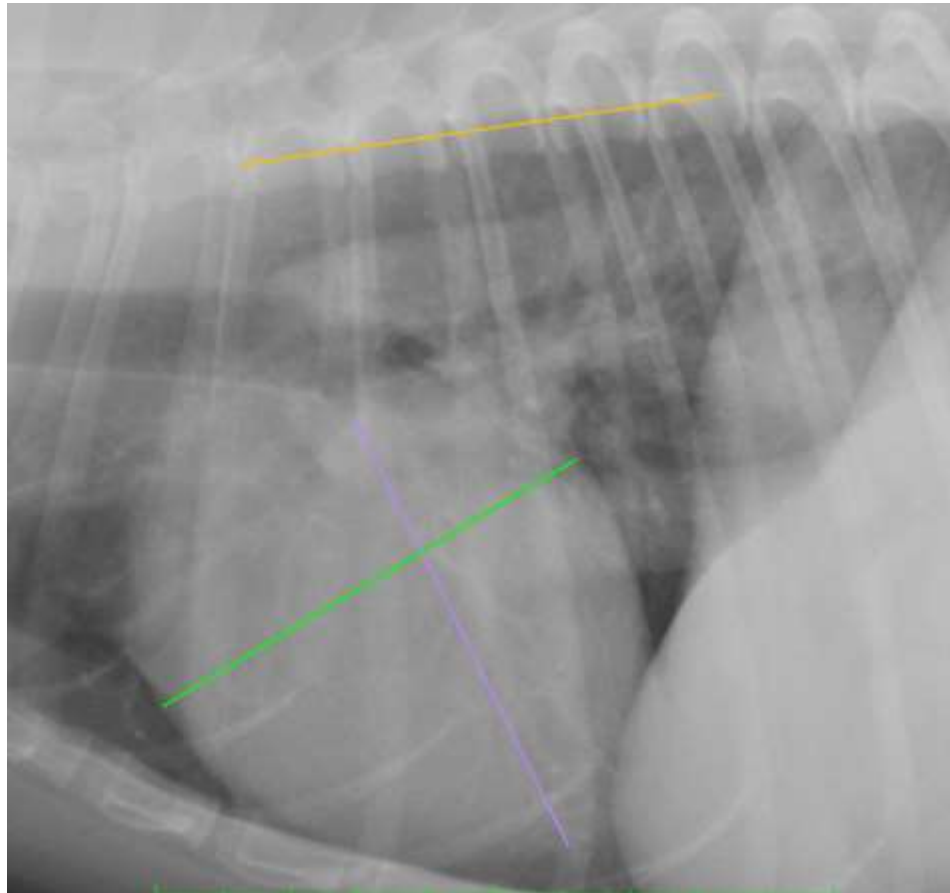
MN

AGE

9 Years

INTERPRETED BY

Nele Eley, DVM
Dr. med. Vet. DipECVDI



HOSPITAL NAME

Reid Veterinary
Hospital

REFERRING VET

Jeff Popowich

INVOICE

47636

DATE

10-1-21

The information and recommendations provided are based on the images presented by the referring veterinarian. No evaluation can be communicated regarding pathology that was not visible in the image/video clips provided.

Thank you for this referral. If the clinical or image interpretation does not parallel your findings or if I can be of any further assistance please contact me.

Nele Eley, DVM, Dr. med. vet., DipECVDI
European Specialist in Veterinary Diagnostic Imaging, Cert. Radiology,
Senior lecturer University of Giessen, Germany, Veterinary Faculty, Department of Radiology
Nele.Eley@sonopath.com