

**PATIENT**

Ashley Lindquist

PRESENTING CLINICAL SIGNS

Wretching, coughing, hacking for several months.
Abnormal PE/Chem/CBC/UA Results: Quiet lung sounds. Bloodwork normal.

SPECIES

Canine

RADIOGRAPHIC STUDY OF THE THORAX

Right/left lateral and ventrodorsal views totaling 3 images available for review.

BREEDCatahoula Leopard
Dog**RADIOGRAPHIC FINDINGS**

The surrounding bony structures are within normal limits.

The extrathoracic soft tissues present homogeneous without abnormalities.

The heart is of normal size and shape and there is no evidence of cardiac chamber or vascular enlargement. The vertebral heart score is 9.9. The pulmonary vasculature is within normal limits.

SEX

FS

The cranial mediastinum presents the expected soft tissue opacity. The mediastinal width is less than twice the width of the vertebral column at the same level.

AGE

14 Years

The trachea is normal in diameter and presents the anticipated course. The luminal outline of the trachea is smooth.

The bronchial tree presents with thin walls and tapers uniformly towards the periphery as expected.

INTERPRETED BYNele Eley, DVM
Dr. med. Vet. DipECVDI

The lung parenchyma presents the expected architecture and opacity. The intrapulmonary vascular branching is seen up to the third order lung vessels.

The diaphragm is well delineated with even surface and the expected mild cranial bulging of the diaphragmatic cupola.

HOSPITAL NAMEPinebrook Animal
Hospital**RADIOGRAPHIC DIAGNOSIS**

- Normal age related thorax.

REFERRING VET

Dr. Britt Dubil

INTERPRETATION OF THE FINDINGS & FURTHER RECOMMENDATIONS

The radiographic study of the thorax reveals no evidence of structural bronchopulmonary or cardiovascular pathology. The radiographic presentation of the lung is considered within age related normal limits. Radiographically occult disease cannot be ruled out. The possibility of upper respiratory tract disease including laryngeal dysfunction should be considered.

INVOICE

47633

DATE

10-1-21



PATIENT

Ashley Lindquist

SPECIES

Canine

BREED

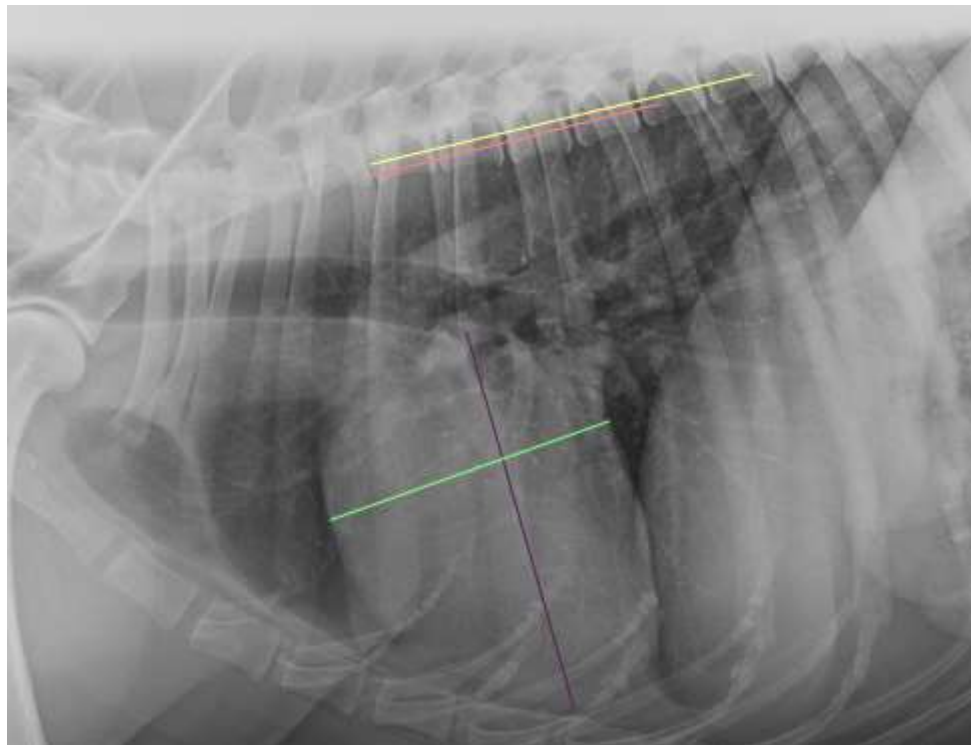
Catahoula Leopard
Dog

SEX

FS

AGE

14 Years



INTERPRETED BY

Nele Eley, DVM
Dr. med. Vet. DipECVDI

The information and recommendations provided are based on the images presented by the referring veterinarian. No evaluation can be communicated regarding pathology that was not visible in the image/video clips provided.

Thank you for this referral. If the clinical or image interpretation does not parallel your findings or if I can be of any further assistance please contact me.

HOSPITAL NAME

Pinebrook Animal
Hospital

Nele Eley, DVM, Dr. med. vet., DipECVDI
European Specialist in Veterinary Diagnostic Imaging, Cert. Radiology,
Senior lecturer University of Giessen, Germany, Veterinary Faculty, Department of Radiology
Nele.Eley@sonopath.com

REFERRING VET

Dr. Britt Dubil

INVOICE

47633

DATE

10-1-21