



**PATIENT**

Ryleigh Robertson

**PRESENTING CLINICAL SIGNS**

non weight bearing on left hindlimb, swollen 3rd digit of LHL, mildly enlarged popliteal lymph node, cranial drawer/tibial thrust- absent on left stifle

**SPECIES**

Canine

**RADIOGRAPHIC STUDY OF THE HIND PAWS**

Mediolateral and craniocaudal views of the stifle joints, ventrodorsal views of the pelvis, mediolateral and dorsoplantar views of the hind paws totaling 8 images available for review.

**BREED**

Rottweiler Mix

Hind paw interpretation requested.

**SEX**

Female Spayed

**RADIOGRAPHIC FINDINGS**

Moderate soft tissue swelling is seen circumferential to the 3<sup>rd</sup> digit in the left hind paw. The soft tissue swelling extends from the distal phalanx up to the metatarsophalangeal joint and extends into the interdigital areas between the 2<sup>nd</sup> and 3<sup>rd</sup> and 3<sup>rd</sup> and 4<sup>th</sup> digits. No osseous abnormalities are seen. There is no evidence of aggressive osteolytic or osteoarthritic changes. No foreign material is noted.

**AGE**

5 Years

The left popliteal lymph node is enlarged.

**RADIOGRAPHIC DIAGNOSIS**

- Digital soft tissue swelling of the 3<sup>rd</sup> digit in the left hind paw.
- Left popliteal lymphadenomegaly.

**INTERPRETED BY**

Nele Eley, DVM  
Dr. med. Vet. DipECVDI

**INTERPRETATION OF THE FINDINGS & FURTHER RECOMMENDATIONS**

Unspecific soft tissue swelling is revealed in the radiographic study circumferential to the 3<sup>rd</sup> digit in the left hind paw. Cellulitis is a primary differential diagnosis. Soft tissue neoplasia and trauma cannot be ruled out entirely as differential diagnoses. Further definition by means of thorough clinical inspection at tissue sampling for cytology or biopsy could be considered.

**HOSPITAL NAME**

St. Catherine's Animal  
Hospital

Consider also fine needle aspiration of the left popliteal lymph node in order to differentiate between reactive hyperplasia and metastatic disease if not performed already.

**REFERRING VET**

Dr. Jui Gokhale

**INVOICE**

56064

**DATE**

1-9-23



**PATIENT**

Ryleigh Robertson

**SPECIES**

Canine

**BREED**

Rottweiler Mix

**SEX**

Female Spayed

**AGE**

5 Years

**INTERPRETED BY**

Nele Eley, DVM  
Dr. med. Vet. DipECVDI

**HOSPITAL NAME**

St. Catherine's Animal  
Hospital

**REFERRING VET**

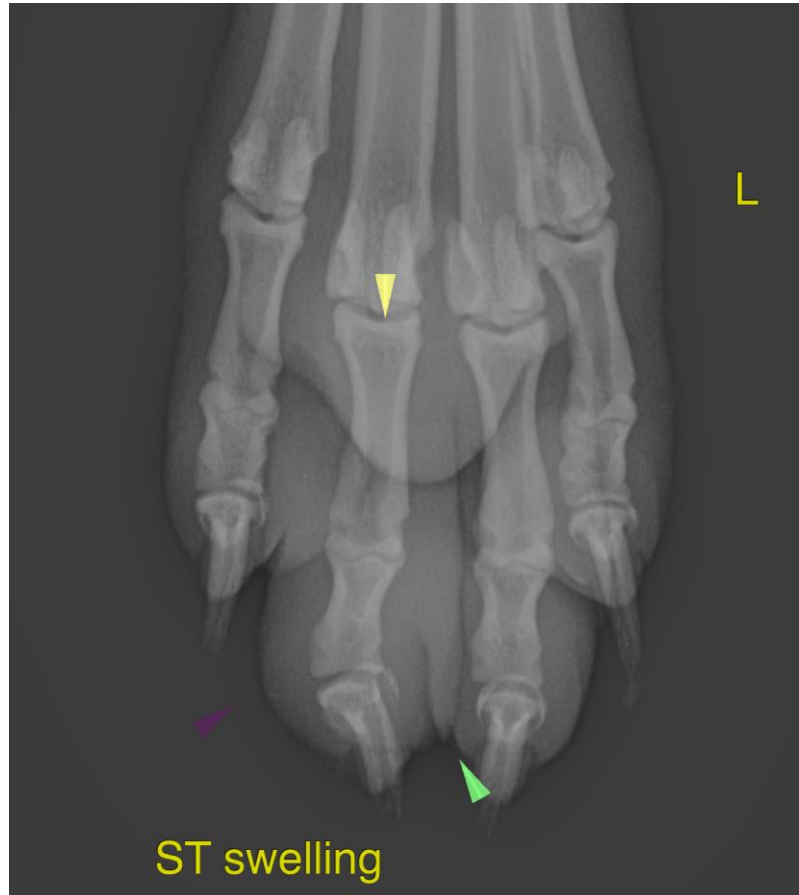
Dr. Jui Gokhale

**INVOICE**

56064

**DATE**

1-9-23



The information and recommendations provided are based on the images presented by the referring veterinarian/sonographer. No evaluation can be communicated regarding pathology that was not visible in the image/video clips provided.

Thank you for this referral. If the clinical or image interpretation does not parallel your findings or if I can be of any further assistance please contact me.

**Nele Eley**, DVM, Dr. med. vet., DipECVDI  
European Specialist in Veterinary Diagnostic Imaging, Cert. Radiology,  
Senior lecturer University of Giessen, Germany, Veterinary Faculty, Department of Radiology  
Nele.Eley@sonopath.com