



PATIENT

Roxy Bondareva

PRESENTING CLINICAL SIGNS

vomiting for 2 days about 4 times, started with vomiting food and then bile. Slight abdominal pain, dehydration 7%. need to rule out foreign body vs others.

SPECIES

Feline

RADIOGRAPHIC STUDY OF THE ABDOMEN

Right/left lateral and ventrodorsal views of the abdomen totaling 4 images available for review.

BREED

Abyssinian

RADIOGRAPHIC FINDINGS

The abdominal serosal detail is maintained.

SEX

Female

The liver and kidneys present within normal limits.

Mild gastric aerophagia is noted.

The small intestinal loops are evenly distributed throughout the mid abdomen. No overt plication is seen. There is no evidence of abnormal dilation or radiopaque foreign material.

AGE

11 Months

A moderate amount of fecal matter is seen within the colon.

The urinary bladder presents within normal limits.

INTERPRETED BY

Nele Eley, DVM
Dr. med. Vet. DipECVDI

RADIOGRAPHIC DIAGNOSIS

- Normal radiographic presentation of the gastrointestinal tract.

HOSPITAL NAME

Truscott Animal
Hospital

INTERPRETATION OF THE FINDINGS & FURTHER RECOMMENDATIONS

The radiographic study is negative for direct signs of mechanical ileus. Linear material and subileus remain a potential even in light of negative radiographic findings at this point. Narrow clinical monitoring and radiographic recheck or abdominal ultrasound could be considered in case of persisting or deteriorating clinical signs.

REFERRING VET

Dr. Medhat Meawad

INVOICE

56059

DATE

1-9-23



PATIENT

Roxy Bondareva

SPECIES

Feline

BREED

Abyssinian

SEX

Female

AGE

11 Months

INTERPRETED BY

Nele Eley, DVM
Dr. med. Vet. DipECVDI

HOSPITAL NAME

Truscott Animal
Hospital

REFERRING VET

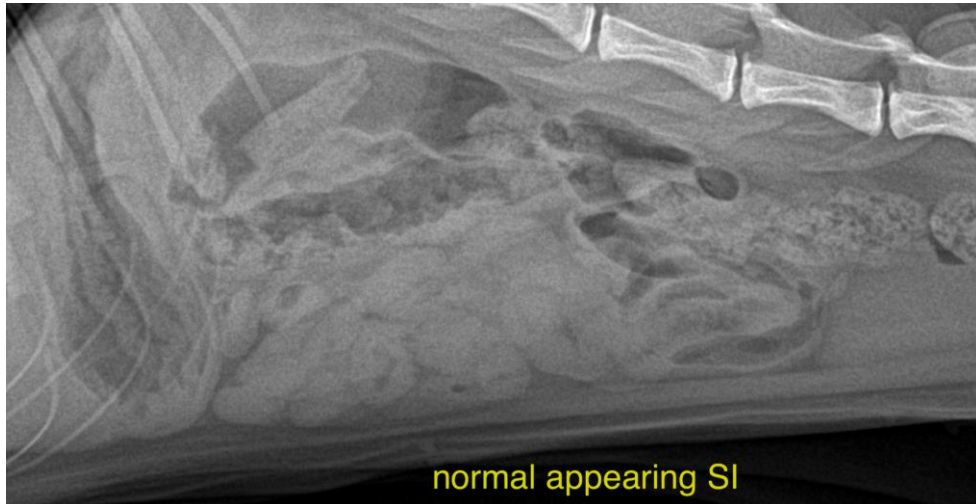
Dr. Medhat Meawad

INVOICE

56059

DATE

1-9-23



The information and recommendations provided are based on the images presented by the referring veterinarian/sonographer. No evaluation can be communicated regarding pathology that was not visible in the image/video clips provided.

Thank you for this referral. If the clinical or image interpretation does not parallel your findings or if I can be of any further assistance please contact me.

Nele Eley, DVM, Dr. med. vet., DipECVDI
European Specialist in Veterinary Diagnostic Imaging, Cert. Radiology,
Senior lecturer University of Giessen, Germany, Veterinary Faculty, Department of Radiology
Nele.Eley@sonopath.com